

Chapter 3

Gastric Fistulas

Nadim Al Hajjar

Vlad-Radu Puia

Cristian Tefas

Marcel Tantau

Cosmin Caraiani

Florin Graur

Introduction

Gastrointestinal fistulas are potentially catastrophic conditions and continue to be associated with high morbidity and mortality rates, and the topic is still of great interest to the surgeon in spite of numerous publications about it. In the last four decades the mortality associated with gastrointestinal fistulas has diminished from 40% to 60% to approximately 15% to 20% [1]. This improvement in prognosis is attributable to general advances in fluid and electrolyte/acid-base therapy, blood administration, critical care, ventilatory management, antibiotic regimens, and nutritional management. Formerly, malnutrition and electrolyte imbalance were the causes of death in the majority of these patients. In the present era of fistula treatment, mortality is largely attributable to uncontrolled sepsis and sepsis-associated malnutrition. Sepsis is still responsible for almost 80% of all deaths in fistula patients [2]. In this chapter we will be referring especially to gastric fistulas as a postoperative complication.

Definition and Classification

A fistula is an abnormal connection between two structures. Enteric (or gastrointestinal) fistulas are aberrant communications between the gastrointestinal tract and any other hollow abdominal organ, abdominal cavity, chest or skin.

Gastrointestinal fistulas can be classified by their anatomic characteristics, and they are either internal or external (enterocutaneous). Fistulas can be classified also according to the anatomical location (gastric, pancreatic, duodenal, jejunal, ileal or colonic), output (high output >500ml / 24h, moderate output 200-500ml/24 h and low output <500ml / 24 h) or as primary (due to intestinal disease processes), or secondary (surgery) [3, 4]. (Table 1)

Table 1. *Classification of intestinal fistulas.*

Debit of drainage in 24 h	Anatomical location	Etiology
High >500 ml	Internal	Primary - Type I
Moderate 200 - 500 ml	External	Secondary - Type II
Low <200 ml		

Etiology

The majority of gastric fistulas occur after surgical, endoscopic, or interventional procedures. Postoperative anastomotic or suture line leaks account for 80% to 85% of all such fistulas, most commonly after operations for cancer.

Surgical Causes

Fistulas can occur at any time following gastrointestinal surgery. The time elapsed to fistula appearance is an important guideline for management and prognosis. Early fistulae arising in the first 48 hours post-surgery can be considered as technical errors and would occasionally require further surgical intervention [5, 6].

In partial gastrectomies, Pickleman et al reported a 1.3% anastomotic leak rate, all from the gastrojejunostomy. After total gastrectomy with Roux-en-Y esophagojejunostomy, anastomotic leaks occurred in 4.8% [7]. Bariatric operations for morbid obesity may result in gastric staple line disruption in the early postoperative period or many months after surgery. Importantly, early anastomotic leaks after gastrojejunostomy in this patient population are highly morbid and often lethal [8]. Leak rate as high as 6% has been reported after divided gastric bypass from the gastrojejunostomy [9]. Duodenal stump leakage is also a well-known problem although the overall incidence has declined. In a high-risk patient, morbidity and mortality can be decreased and possibly prevented by placement of a duodenostomy tube along with closed suction drains external to the duodenum.

The extension of laparoscopic techniques to gastric surgery has not eliminated the risk of perforation and subsequent fistula formation. Veress needle insertion may result in the perforation of any intraabdominal organ, as can the other varied techniques of abdominal access for laparoscopy, especially in a reoperative abdomen.

Endoscopic/Interventional Causes

Due to the wall thickness and compliance the stomach makes an excellent organ for endoscopy with a low incidence of injury. Nevertheless, endoscopic polypectomy or attempts at tumor removal with a snare and cautery may cause either immediate full-thickness perforation or deep penetration with thermal injury to the remaining tissue and subsequent delayed perforation and fistula. Percutaneous endoscopic gastrostomy (PEG) tube placement has also resulted in perforation, either from dislodgement of the tube before complete gastric adhesion to the abdominal wall or from trauma during placement.

Clinical presentation and Diagnosis

First we have to suspect the patient of having a gastrointestinal fistula, and after that a thorough clinical examination and medical history is needed. A gastrointestinal fistula can be obvious in some patients and extremely difficult to identify in others. Symptoms as pain, fever and illness are common. External fistulas are generally easier to diagnose due to the unusual effluent from drainage sites or abdominal incisions (purulent discharge and/or discharge of intestinal contents and/or gas), cellulitic inflammation, and sepsis [10]. Intraoperative perforations are best handled by recognizing the injury before the end of the procedure, and immediately repairing, suturing, or reinforcing weakened tissues.

Many techniques are available that can be useful in confirming the diagnosis and identifying the intrinsic anatomical and pathological features of a fistula

(Table 2) [11].

Table 2. *Clinical-instrumental methods used for diagnosing gastrointestinal fistulas.*

<ul style="list-style-type: none">• Monitor<ul style="list-style-type: none">—fistula output volume—fistula aspect (color, etc.)—water-electrolyte balance—biochemical evaluation (amylase, lipase, bilirubin, pH, etc.)—infection status—nutritional/metabolic status• Methylene blue test• Upper or lower gastrointestinal endoscopy• Digestive tract x rays with water soluble contrast medium• Fistulography with water soluble contrast medium• Ultrasonography• Computerized axial tomography• Magnetic resonance imaging

In literature risk factors for postoperative fistula formation are as follow: malnutrition, malignant disease, inflammatory bowel disease, immunocompromised state, infection, bacterial peritonitis, renal insufficiency, cirrhosis, mesenteric vascular disease, previous surgery, smoking, alcoholism, low quality suture and inadequate surgical training or experience. Patients undergoing emergency surgery may also be more likely to develop a fistula than patients undergoing elective surgery.

Treatment

The management of gastrointestinal fistulas is complex and requires input from a wide range of personnel, with attention to the control of sepsis, fluid and electrolyte balance, maintenance of nutrition, and to the wound/stoma care (Table 3).

Table 3. *Members of the multidisciplinary team.*

Enterostomal therapists
Surgeons/medical personnel
Nurses
Radiologists
Nutritionists
Infectious disease team
Psychiatrists/psychologists

Regardless of the pathogenesis, the management most often requires considerable lengths of hospital stay and extensive multidisciplinary input. The development of an intestinal fistula following surgery is a devastating complication for the patient and their family. It may lead to significant anxiety, loss of self-esteem and depression.

The treatment can be divided in conservative, endoscopic, interventional imaging and surgical, but these options can change from one day to another.

Conservative Treatment

A very useful acronym in the management of patients with gastrointestinal fistulas is “SNAP”; S is for control of sepsis and appropriate skin care; N is for nutrition, ideally via the enteral route (if not, then parenterally or a combination of both); A is to define the underlying anatomy; P is for a definite plan to deal with the fistula [12].

Patients with gastric fistulas experience significant fluid and electrolyte imbalances which must carefully monitored and replaced. Resuscitation aims to restore intravascular fluid volume and to ensure a urine output of 30 mL/h or higher. The circulation volume deficits result from extracellular fluid losses, and replacement is best achieved with isotonic crystalloid solutions, such as normal saline or lactated Ringer solution. All these replacements are best done in the Intensive Care Unit (ICU).

Uncontrolled sepsis is a major cause of mortality in patients with gastric fistulas therefore patients are treated with broad-spectrum antibiotics. Tachycardia, persistent fever and leukocytosis usually shows inadequate control of the fistula or abscess formation (of postoperative intra-abdominal abscesses, 15% are reported to be associated with fistulas).

Control of entero-cutaneous fistula drainage is individualized according to the patient and the fistula output. Attempts should be made to decrease fistula output by placing of enteric drainage tubes proximal to the fistula. Nasogastric or naso-jejunal tubes are usually placed, and the patient is given nothing by mouth while total parenteral nutrition (TPN) is initiated. The goal of controlling enterocutaneous fistula output is to prevent the intraperitoneal accumulation of intestinal contents and to protect the skin from the effects of the intestinal contents. A fistula should be exteriorized on a flat portion of the abdominal wall with avoidance of bony prominences and skin folds. This permits secure application of an ostomy bag or other device to collect and monitor fluids and protect the skin. Specialized nursing assistance by an enterostomal therapist or wound care specialist is frequently necessary and can be quite helpful in the management of these often complex wounds [13]. Furthermore sponge vacuum dressings can be applied to control fistula drainage and to keep the surrounding skin dry. This also helps healing the fistula and the patients can be discharged with this system in place.

Nutritional Support

Adequate nutritional support has a significant impact on the outcome of patients with gastrointestinal fistulas. Whenever possible, enteral nutrition is preferable to parenteral nutrition and probably decreases the incidence of multisystem organ failure and sepsis if administered appropriately. When oral intake is possible the World Health Organization recommends oral rehydration solution which contains 40 g/L of glucose, 90 mEq/L of sodium, 20 mEq/L potassium, and has an

osmolality of 311 mOsm. Patients with localized infections and malnutrition require 30-40 kcal/kg/day, whereas patients with uncontrolled sepsis, shock, and multiple organ failure require 40-45 kcal/kg/day. The total caloric needs are met by glucose and fats. Glucose provides approximately two thirds to three fourths of the total caloric requirements, and lipids provide the remainder.

Enteral nutrition can be given for upper gastrointestinal fistulas, especially when the feeding tube can be placed beyond the fistula. In general, when possible feeding tubes should be placed beyond the ligament of Treitz to decrease the potential risk for aspiration.

Total parenteral nutrition (TPN) provides initial nutritional support while control of infection and maturation of the fistula tract take place. Normal intestinal motility and function usually return once abdominal sepsis is controlled and fluid and electrolyte imbalances are corrected.

Because both enteral and parenteral feeding has advantages and disadvantages, by using a combination of approaches, adequate nutrition can be maintained throughout the patient's course.

Pharmacologic support

The concept of using somatostatin (14-amino-acid peptide) to inhibit pancreatic exocrine secretion in the treatment of gastrointestinal fistulas was first introduced in 1979 by Klempa et al [14]. A subcutaneous dose (100-250 µg) of octreotide is administered every 8 hours. Various studies have reported a demonstrable decrease in fistula output of as much as 50% within 24-48 hours of initiating treatment [15]. Side effects include hyperglycemia, decreased bowel motility and elevated cholesterol levels.

Proton pump inhibitors or histamine H₂-receptor antagonists are used to reduce gastric acid production, slow transit, and to reduce gastric secretions. These medications may be useful in decreasing fistula output, particularly with

proximal fistulas or when the amount of gastric secretions is high.

Other agents such as cyclosporine, azathioprine, 6-mercaptopurine and infliximab are used in the gastrointestinal fistulas healing process in patients with Crohn disease [16, 17].

After sepsis has been controlled and diagnostic studies have been completed, management of a fistula should follow a conservative course. An opportunity for spontaneous healing should be permitted. Factors that may adversely affect spontaneous closure rates are listed in Table 4.

Table 4. Factors that may adversely affect spontaneous closure rates [18-20].

Anatomical	Other
<ul style="list-style-type: none"> • Discontinuity of bowel ends • Complete disruption • Distal obstruction (caused by an obstacle downstream or discontinuity between parts of the gastrointestinal tract) • Intra-abdominal foreign body • Radiation • Underlying IBD • Uncontrolled sepsis, with or without abscess formation • Lateral fistula • Complex fistula • Associated abscess • Adjacent bowel diseased • Poor bowel vascularization • Fistula tract <2 cm • Defect >1 cm • Epithelialization of muco-cutaneous fistula tract • Drainage through large abdominal wall defect (multiple orifices) • Internal fistulae • Fistula site (gastric, lateral duodenal, or ileal) 	<ul style="list-style-type: none"> • Cancer • Chemotherapy • Fistula fluid infected • Hypoproteinemia • Large and early leakage of anastomosis • Diabetes patients • Corticosteroids • Renal failure • Output may prognosticate closure

An easy-to-remember acronym for failure of an enterocutaneous fistula to close spontaneously is FRIENDS [21]: the presence of a foreign body within the tract or adjacent to it, previous radiation exposure of the site, ongoing inflammation (most commonly from Crohn disease) or infection that contributes to a catabolic state, epithelialization of the fistula tract (particularly if the fistula tract is less than 2 cm long), neoplasm, distal intestinal obstruction, and pharmacologic doses of steroids.

Endoscopic Treatment

Underlying causes for gastric leaks and perforations include gastric ulcers, gastric cancer and trauma. There are numerous iatrogenic causes as well, such as bariatric surgery, gastrojeunal leaks after Roux-en-Y gastric bypass and perforations after endoscopic dilatation or endoscopic resection techniques. The options for endoscopic therapy are similar to those used in esophageal or colorectal leaks and perforations and they include stenting, using either fully or partially covered stents, endoscopic assisted vacuum closure (EVAC), endoscopic clips, suturing or fibrin glue.

Anastomotic leaks following bariatric surgery are usually found along the staple lines and lead to bacterial contamination, abscess formation and thus lack of healing at the leak site. The most commonly used endoscopic technique for managing anastomotic leaks after bariatric surgery is stenting (Figure 1; Figure 2). These work by covering the breach and subsequently restrict leaking. A series of stents manufactured especially for these cases exist, each having a unique design and providing excellent flexibility and conformability to fit in tortuous anatomy. A meta-analysis discussing the use of metallic stents in leaks after bariatric surgery demonstrated a successful leak closure of 88%, 9% of the patients requiring additional surgery to fully close the breach [22]. In different series of patients with anastomotic complications following gastric surgery, stenting was used with a success rate ranging from 70 to 90%, the rest of the patients needing

surgical reinterventions for adequate clinical management [23-26].

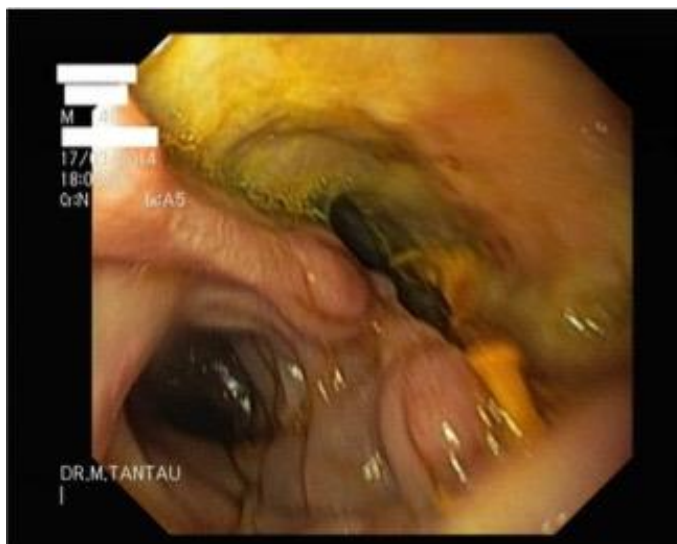

Figure 1. Large parietal defect following gastrectomy for gastric cancer.

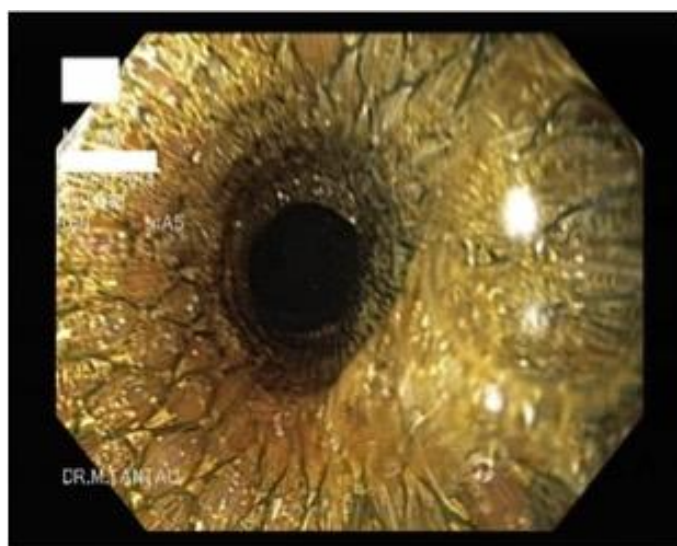


Figure 2. Fully covered metal stent after deployment used to close the fistula.

There is, as always, a risk of migration when using fully covered stents. In such cases, anchoring the stent to the mucosa using endoscopic clips is possible. Using partially covered stents leads to a decrease in the risk of migration, but they may become lodged in the digestive tract due to epithelial over- and ingrowth. As such, most stents are left in place for 6-8 weeks, which is considered to be enough time for the wound to heal but not enough to develop excess tissue.

Stents are usually well tolerated, with discomfort, pain, dysphagia and regurgitation being the main complaints after placement. If the symptoms are persistent or worsen over time, stents should be revisited, as to ensure that they have not migrated or embedded themselves into the gastric wall.

Iatrogenic perforations after different endoscopic resection techniques can be managed depending on their correspondent size. For perforations up to 10 mm, through-the-scope clips (TTSC) usually suffice, when they have been diagnosed during or within 12 hours of endoscopy. A conservative approach may be considered if the perforation is recognized later than 12 hours. For perforations between 10 and 30 mm, over-the-scope clips (OTSC) can be used [27] (Figure 3; Figure 4; Figure 5; Figure 6). Different accessories may be used to facilitate grasping of the edges and pulling inside the device's cap, in order to properly deploy the clip. An alternative to OTSC, if this is not available, is a combined technique using TTSC and an endoloop [28, 29]. In this case, after placing clips at the edge of the lesion in a circular pattern, an endoloop is placed over them and deployed in order to tighten all the clips together. Other options for the nonsurgical treatment of gastric perforations include self-expandable metal or plastic stents, which are indicated in cases of perforation following endoscopic dilatations.

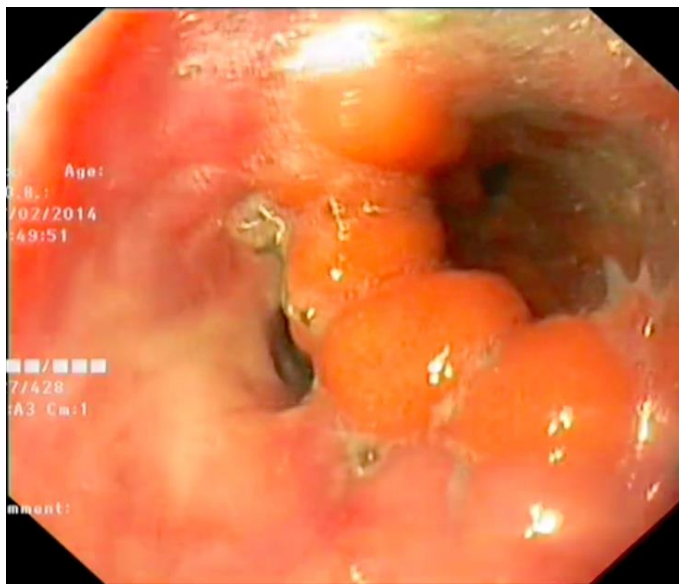


Figure 3. Endoscopic view of a fistula after sleeve gastrectomy, which was subsequently successfully closed using over-the-scope clips.

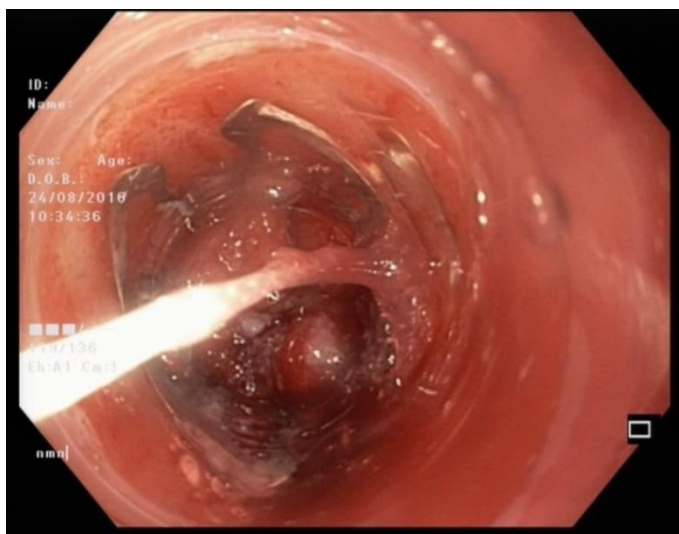


Figure 4. Over-the-scope clip mounted on the distal end of the endoscope before deployment. The threads seen in the center of the image are used to deploy the clip.

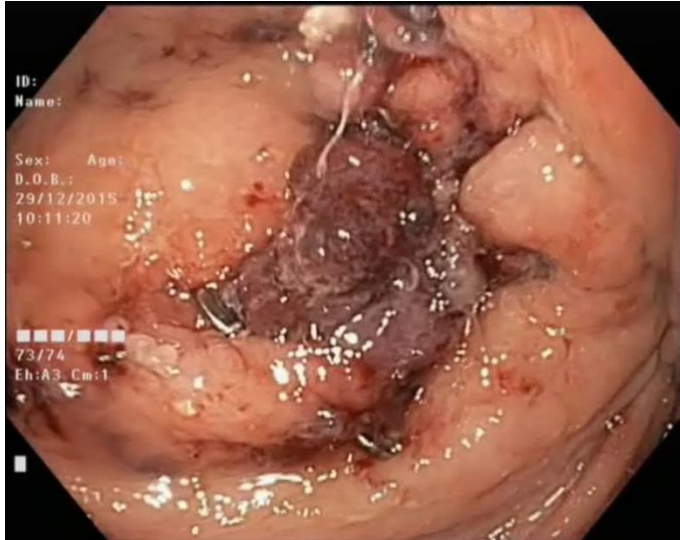


Figure 5. View of an over-the-scope clip after deployment used to successfully close a fistula after bariatric surgery.

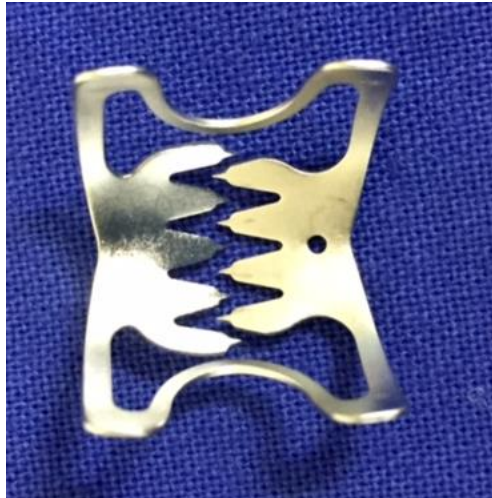

Figure 6. Over-the-scope clip.

TTSC (Figure 7) are usually too small for the large parietal defects that are frequently encountered after bariatric surgery and cannot provide the necessary traction in order to completely and efficiently close such a breach. However, OTSC have been used successfully in several case reports, with a success rate of

80% [30]. Gastrointestinal and gastrocutaneous fistulas have been successfully managed as well using OTSC, with clinical resolution in 74% of cases [31].

Endoscopic suturing using the available devices has recently gained popularity. A large multicenter study reviewed 122 patients who underwent endoscopic suturing for management of gastrointestinal defects. Immediate clinical success was achieved in 79.5% of patients, while long-term clinical success was noted in 78.8%. Clinical success was 93% in perforations and 80% in fistulas, but only 27% in anastomotic leak closure [32].

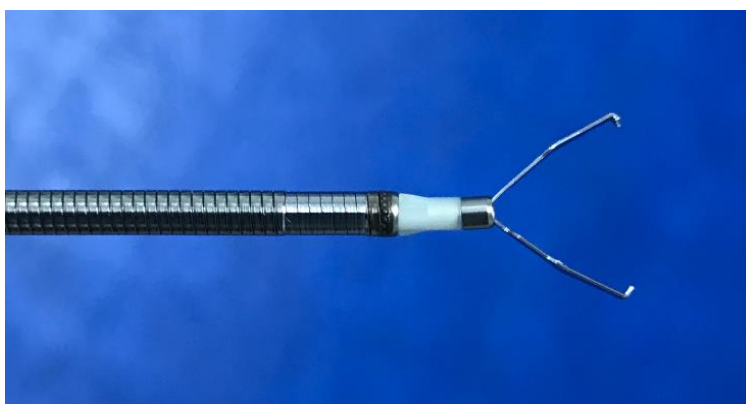


Figure 7. *Through-the-scope endoscopic clip.*

Fibrin glue is a sealant with tissue adhesive capabilities composed of fibrinogen and thrombin, which once injected at the site of the perforation leads to formation of a plug similar to a fibrin clot. Due to modest results when used as a single modality, it is usually used in combination with other endoscopic techniques, such as clipping or stenting [33, 34]. One case series described a method using polyglycolic acid sheets and fibrin glue as a way to treat large perforations and delayed perforations that occur following ESD [35]. In this instance, using a biopsy forceps, the perforation is first packed and covered with polyglycolic acid sheets previously cut into small sized pieces. Fibrinogen is then sprayed over the sheets, in such a manner that it passes through the other

side of the perforation. Thrombin is then injected deeper inside the breach, which when in contact with the fibrinogen solidifies and bonds the pieces of polyglycolic acid together. Fibrin glue was also used successfully in some cases of high-output gastrocutaneous fistulas after vertical gastropasty in morbidly obese patients [36].

EVAC has also proven to be a viable option for use in anastomotic leaks after sleeve gastrectomies, with reported success rates as high as 100%, with an average treatment time of 50 days [37].

For patients with different anatomic particularities or large defects, who do not respond to first line therapy using metallic stents or where percutaneous drainage is impossible, a new safe and effective technique has been described. Using fluoroscopy, a balloon catheter is first inserted inside the breach and the fluid is aspirated. One or two guidewires are then advanced into the collection and then pigtail stents are inserted over them as to drain the remaining fluid. If necessary, prior endoscopic balloon dilatation of the fistula orifice is possible to allow adequate placement of stents [38].

Interventional Radiology

After gastric surgery we can find gastro-jejunal or eso-jejunal fistulas depending of the type of the anastomosis. The evolution of these fistulas can be silent, with minimal symptomatology or devastating with high morbidity and mortality [39]. Because of the potential high risk the radiology must lead to a fast and correct diagnosis. The first step is to perform a contrast study with a water-soluble agent, not barium, because of the risk of chemical peritonitis. The fistula is recognized when the water-based agent is seen outside the intestinal tract. We recommend this test to be done at all the subjects before any oral intake because a small fistula can be without any clinical signs. With the help of this method we will know the localization of the fistula, its size and the

communication with an abscess. In some cases we can find entero-enteral or entero-cutaneous fistulas. The most important echographic sign is the presence of a fluid collection near the anastomosis or in the left upper quadrant (perisplenic) if we are talking about a gastric fistula [40]. We mention that only 50% of gastric fistulas are accompanied by fluid collections. An isolated collection, without increasing volume, is not specific for a fistula. CT-scan is the golden standard, with the highest specificity and sensibility, in the diagnosis of gastric fistulas. The scan is made with thin slices and with oral and intravenous contrast agent. The most important sign of a fistula is the presence of the contrast fluid outside the digestive lumen. The presence of air and fluids next to the anastomosis are both indirect signs of a fistula. Free-air in the abdominal cavity can be present in the first days after surgery, as well as small fluid collections, so these indirect signs must be well balanced. The CT-scan must describe the fistula from the point of view of size, orientation and communication with other organs or formation of intra-abdominal collections.

An important role for interventional radiology is percutaneous drainage (needle puncture) of adjacent fluid, abscesses, and the fistula itself. Fluid collections greatly increase the risk of sepsis and often prevent closure with abscess formation in as many as 44% of fistulas [41]. This can be done under US, CT or fluoroscopic guidance. The puncture route should be meticulously planned, and the shortest pathway chosen from the cross-sectional images. There should be no intervening viscera, bowel, or vital structures such as blood vessels in the path of the needle. Catheter drainage of the fistula can be performed soon after development when repeat surgery may be harmful to the patient.

Interventional radiologic closure procedures use various materials placed along the length of the fistula tract to promote healing.

Closure Materials

Bioadhesives (fibrin glue) - TISSELL (Baxter, Deerfield, Illinois) is available as a preloaded dual-injection syringe that also contains aprotinin, a substance that prevents breakdown of the formed fibrin clot and is rarely associated with anaphylaxis.

- EVICEL (Ethicon, Somerville, New Jersey), does not contain aprotinin and is provided as separate fibrin and thrombin solution vials.

- BioGlue (CryoLife, Kennesaw, Georgia) consists of bovine serum albumin and glutaraldehyde [42].

Extracellular Matrix (ECM) Material is a biologic scaffold of proteoglycan and nonproteoglycan components that provide cellular support and contain growth factors. SurgiSIS (Cook) is an ECM material consisting of freeze-dried decellularized porcine small intestine.

Gelatin Sponge. Gelatin sponge such as Gelfoam (Pfizer, New York, New York) is a low-cost, easily available bioabsorbable material mostly known as an embolic agent to stop hemorrhage, but can also be used as closure material [43].

Surgical Treatment

After all the methods listed above fail to lead to fistula closure or for a definitive treatment the surgery comes into question. As we said before there is no specific algorithm to follow for the treatment of a gastrointestinal fistula and, maybe the most important thing, is that the treatment must be individualized from one patient to another. In Table 5 there is a list of indications for fistula surgical repair [44-46].

Table 5. Indications for fistula surgical repair.

FISTULA CHARACTERISTICS
Complex or multiple fistulas
End fistula (intestinal discontinuity)
Short fistula tract (<2 cm)
Enteral defect >1 cm
Eversion of mucosa
Epithelialization of the fistulous tract
Distal occlusion
Presence of ileus
Diseased adjacent bowel
Fistula arising from stomach, lateral duodenal, near ligament of Treitz, Ileum
Associated abscess
Abdominal wall defect
Open abdomen
Evisceration
Fistula output >500 ml/day
Fistula arising in the first 48 hours after surgery
Chronic fistula (>4-6 weeks)
UNDERLYING DISEASES
Malignancy
Inflammatory bowel disease
Radiation enteritis
Intra-abdominal foreign body
Trauma

The main gastrointestinal fistulas complications requiring surgery are peritonitis, intraabdominal abscesses, gangrene, bleeding or septic status not otherwise curable. In these cases emergency or semi-urgent surgery is generally performed, and the procedures should be limited to controlling sepsis or bleeding and performing a proximal defunctioning stoma. If the patient is stable we should wait 6 to 8 weeks before re-entering the abdominal cavity. Re-entering the abdomen in a patient with gastrointestinal fistula may be quite challenging and the surgeon may worsen the situation creating enterotomies in an attempt to gain

access into the free peritoneal cavity. A new and separate incision can be preferred. After entering the abdominal cavity the plan include lysis of all adhesions, drainage of all abscesses and relief of distal bowel obstruction [47].

The different surgical procedures used in gastrointestinal fistulas treatment are described as follows:

1. The *drainage* of all infected peritoneal fluid is the main procedure because the fistula will never heal in a septic field. The pelvic region, paracolic gutters, and subphrenic spaces must be opened and debrided. Peritoneal debridement, including removal of fibrinous deposits from the parietal and visceral surface is often performed. Intraoperative peritoneal lavage with 0,9% NaCl warm solution reduces the degree of bacterial contamination and removes pus, blood, intestinal juice, fecal material and necrotic tissues [48]. Drains are left to any suspicious areas. Some authors also proposed postoperative continuous peritoneal lavage with the addition of antibiotics as well as low-doses of heparin in an attempt to reduce the risk of persistent or recurrent infections [49].
2. The *exclusion* of an intestinal fistula is indicated in very ill patients, in presence of compromised bowel and sepsis; this procedure usually involves resection of the diseased segment followed by exteriorization of the ends. Surgical exclusion of the gastroduodenal area include pyloric exclusion by stapling the stomach and creating a gastrojejunostomy. This procedure is often used in trauma patients in order to protect a damaged duodenum [50].
3. *Resection* of the anastomotic fistula is sometimes the operation of choice. The affected segment is resected and a new anastomosis is performed, but this technique should not be performed if the new anastomosis is in a contaminated field or if ischemia, tension or edema on the anastomosis are present [34].

4. In patients with complex fistula, high output, poor general conditions, severe lesions of the skin or abdominal wall, an *intestinal bypass* through a laparotomy far from the affected area can be indicated. End-to-side anastomosis of the intestinal segment proximal and distal to the fistula is performed, allowing alternative intestinal transit, and anastomosis is performed in the healthy intestine far from the affected area [51].
5. The simple *closure* of the fistula defect is not recommended by most authors and often placing sutures in the fistulous opening is only a futile exercise that tends to enlarge the opening instead of reducing its size.
6. *Coverage* of the fistula with well-vascularized soft tissue can be employed in particular cases of large fistulas. This solution significantly improves the likelihood of fistula closure. An omental patch when available is a great solution for coverage.

Conclusions

Digestive fistulas have multifactorial etiology and can affect any part of the gastrointestinal tract. The management of gastrointestinal fistulas is challenging and requires daily attention by a senior surgeon. Indications to surgical treatment, timing and choice of operation type cannot be standardized and depends on many factors as shown above. The whole medical team must be in a continuous dialogue about the patient evolution, and they must quickly take adequate decisions if the patient state is modified. Psychologic support of both patient and family is essential. Furthermore digestive fistulas is a vast field of research to improve, not only the diagnosis and treatment, but especially its prevention.

References

- [1] Berry, S. M. and J. E. Fischer, *Enterocutaneous fistulas*. Curr Probl Surg, 1994. 31(6): p. 469-566.
- [2] Reber, H. A., et al., *Management of external gastrointestinal fistulas*. Ann Surg, 1978. 188(4): p. 460-7.
- [3] Polk, T. M. and C. W. Schwab, *Metabolic and nutritional support of the enterocutaneous fistula patient: a three-phase approach*. World J Surg, 2012. 36(3): p. 524-33.
- [4] Lundy, J. B. and J. E. Fischer, *Historical Perspectives in the Care of Patients with Enterocutaneous Fistula*. Clinics in Colon and Rectal Surgery, 2010. 23(3): p. 133-141.
- [5] Sitges-Serra, A., E. Jaurrieta, and A. Sitges-Creus, *Management of postoperative enterocutaneous fistulas: the roles of parenteral nutrition and surgery*. Br J Surg, 1982. 69(3): p. 147-50.
- [6] McIntyre, P. B., et al., *Management of enterocutaneous fistulas: a review of 132 cases*. Br J Surg, 1984. 71(4): p. 293-6.
- [7] Pickleman, J., et al., *The failed gastrointestinal anastomosis: an inevitable catastrophe?* J Am Coll Surg, 1999. 188(5): p. 473-82.
- [8] Cucchi, S. G., et al., *Gastrogastric fistulas. A complication of divided gastric bypass surgery*. Annals of Surgery, 1995. 221(4): p. 387-391.
- [9] Kirkpatrick, J. R. and J. L. Zapas, *Divided gastric bypass: a fifteen-year experience*. Am Surg, 1998. 64(1): p. 62-5; discussion 65-6.
- [10] Rubelowsky, J. and G. W. Machiedo, *Reoperative versus conservative management for gastrointestinal fistulas*. Surg Clin North Am, 1991. 71(1): p. 147-57.
- [11] Falconi, M., et al., *Management of digestive tract fistulas. A review*. Digestion, 1999. 60 Suppl 3: p. 51-8.
- [12] Kaushal, M. and G. L. Carlson, *Management of enterocutaneous fistulas*. Clin Colon Rectal Surg, 2004. 17(2): p. 79-88.

- [13] D'Harcour, J. B., J. H. Boverie, and R. F. Dondelinger, *Percutaneous management of enterocutaneous fistulas*. AJR Am J Roentgenol, 1996. 167(1): p. 33-8.
- [14] Klempa, I., U. Schwedes, and K. H. Usadel, [*Prevention of postoperative pancreatic complications following duodenopancreatectomy using somatostatin*]. Chirurg, 1979. 50(7): p. 427-31.
- [15] Paran, H., et al., *Octreotide for treatment of postoperative alimentary tract fistulas*. World J Surg, 1995. 19(3): p. 430-3; discussion 433-4.
- [16] Present, D. H. and S. Lichtiger, *Efficacy of cyclosporine in treatment of fistula of Crohn's disease*. Dig Dis Sci, 1994. 39(2): p. 374-80.
- [17] Lichtenstein, G. R., et al., *Infliximab maintenance treatment reduces hospitalizations, surgeries, and procedures in fistulizing Crohn's disease*. Gastroenterology, 2005. 128(4): p. 862-9.
- [18] Berry, S. M. and J. E. Fischer, *Classification and pathophysiology of enterocutaneous fistulas*. Surg Clin North Am, 1996. 76(5): p. 1009-18.
- [19] Ysebaert, D., et al., *Management of digestive fistulas*. Scand J Gastroenterol Suppl, 1994. 207: p. 42-4.
- [20] Martineau, P., J. A. Shwed, and R. Denis, *Is octreotide a new hope for enterocutaneous and external pancreatic fistulas closure?* Am J Surg, 1996. 172(4): p. 386-95.
- [21] Lee, S.-H., *Surgical Management of Enterocutaneous Fistula*. Korean Journal of Radiology, 2012. 13(Suppl 1): p. S17-S20.
- [22] Puli, S. R., I. S. Spofford, and C. C. Thompson, *Use of self-expandable stents in the treatment of bariatric surgery leaks: a systematic review and meta-analysis*. Gastrointest Endosc, 2012. 75(2): p. 287-93.
- [23] Aryaie, A. H., et al., *Efficacy of endoscopic management of leak after foregut surgery with endoscopic covered self-expanding metal stents (SEMS)*. Surg Endosc, 2017. 31(2): p. 612-617.
- [24] Yimcharoen, P., et al., *Endoscopic stent management of leaks and anastomotic strictures after foregut surgery*. Surg Obes Relat Dis, 2011. 7(5): p. 628-36.

- [25] Boules, M., et al., *Endoscopic management of post-bariatric surgery complications*. World Journal of Gastrointestinal Endoscopy, 2016. 8(17): p. 591-599.
- [26] Chang, J., et al., *Endoscopic stents in the management of anastomotic complications after foregut surgery: new applications and techniques*. Surg Obes Relat Dis, 2016. 12(7): p. 1373-1381.
- [27] Paspatis, G. A., et al., *Diagnosis and management of iatrogenic endoscopic perforations: European Society of Gastrointestinal Endoscopy (ESGE) Position Statement*. Endoscopy, 2014. 46(8): p. 693-711.
- [28] Ye, L. P., et al., *Endoscopic full-thickness resection with defect closure using clips and an endoloop for gastric subepithelial tumors arising from the muscularis propria*. Surg Endosc, 2014. 28(6): p. 1978-83.
- [29] Ladas, S. D., et al., *Combined use of metallic endoclips and endoloops using a single-channel scope in closing iatrogenic perforations and fistulas: two case reports and a literature review*. Eur J Gastroenterol Hepatol, 2014. 26(1): p. 119-22.
- [30] Keren, D., et al., *Over-the-Scope Clip (OTSC) System for Sleeve Gastrectomy Leaks*. Obes Surg, 2015. 25(8): p. 1358-63.
- [31] Surace, M., et al., *Endoscopic management of GI fistulae with the over-the-scope clip system (with video)*. Gastrointest Endosc, 2011. 74(6): p. 1416-9.
- [32] Sharaiha, R. Z., et al., *A Large Multicenter Experience With Endoscopic Suturing for Management of Gastrointestinal Defects and Stent Anchorage in 122 Patients: A Retrospective Review*. J Clin Gastroenterol, 2016. 50(5): p. 388-92.
- [33] Spyropoulos, C., et al., *Management of gastrointestinal leaks after surgery for clinically severe obesity*. Surg Obes Relat Dis, 2012. 8(5): p. 609-15.
- [34] Bhayani, N. H. and L. L. Swannstrom, *Endoscopic therapies for leaks and fistulas after bariatric surgery*. Surg Innov, 2014. 21(1): p. 90-7.
- [35] Takimoto, K. and A. Hagiwara, *Filling and shielding for postoperative gastric perforations of endoscopic submucosal dissection using polyglycolic acid sheets and fibrin glue*. Endoscopy International Open, 2016. 4(6): p. E661-E664.

- [36] Papavramidis, S. T., et al., *Endoscopic fibrin sealing of high-output non-healing gastrocutaneous fistulas after vertical gastropasty in morbidly obese patients*. *Obes Surg*, 2001. 11(6): p. 766-9.
- [37] Leeds, S. G. and J. S. Burdick, *Management of gastric leaks after sleeve gastrectomy with endoluminal vacuum (E-Vac) therapy*. *Surgery for Obesity and Related Diseases*. 12(7): p. 1278-1285.
- [38] Bouchard, S., et al., *Mo1565 Trans-Fistulary Drainage for Post-Bariatric Abdominal Collections Communicating With the Upper Gastrointestinal Tract*. *Gastrointestinal Endoscopy*. 81(5): p. AB468-AB469.
- [39] Marshall, J. S., et al., *Roux-en-Y gastric bypass leak complications*. *Arch Surg*, 2003. 138(5): p. 520-3; discussion 523-4.
- [40] Blachar, A., et al., *Gastrointestinal complications of laparoscopic Roux-en-Y gastric bypass surgery: clinical and imaging findings*. *Radiology*, 2002. 223(3): p. 625-32.
- [41] Kerlan, R. K., Jr., et al., *Abdominal abscess with low-output fistula: successful percutaneous drainage*. *Radiology*, 1985. 155(1): p. 73-5.
- [42] Passage, J., et al., *Bioglue: a review of the use of this new surgical adhesive in thoracic surgery*. *ANZ J Surg*, 2005. 75(5): p. 315-8.
- [43] Lisle, D. A., et al., *Percutaneous gelfoam embolization of chronic enterocutaneous fistulas: report of three cases*. *Dis Colon Rectum*, 2007. 50(2): p. 251-6.
- [44] Falconi, M. and P. Pederzoli, *The relevance of gastrointestinal fistulae in clinical practice: a review*. *Gut*, 2001. 49(Suppl 4): p. iv2-iv10.
- [45] Campos, A. C., M. M. Meguid, and J. C. Coelho, *Factors influencing outcome in patients with gastrointestinal fistula*. *Surg Clin North Am*, 1996. 76(5): p. 1191-8.
- [46] de Costa, A., *Making a virtue of necessity: managing the open abdomen*. *ANZ J Surg*, 2006. 76(5): p. 356-63.
- [47] Rolandelli, R. and J. J. Roslyn, *Surgical management and treatment of sepsis associated with gastrointestinal fistulas*. *Surg Clin North Am*, 1996. 76(5): p. 1111-22.

- [48] Hau, T., D. H. Ahrenholz, and R. L. Simmons, *Secondary bacterial peritonitis: the biologic basis of treatment*. Curr Probl Surg, 1979. 16(10): p. 1-65.
- [49] Hallerback, B., et al., *A prospective randomized study of continuous peritoneal lavage postoperatively in the treatment of purulent peritonitis*. Surg Gynecol Obstet, 1986. 163(5): p. 433-6.
- [50] Chung, M. A. and H. J. Wanebo, *Surgical management and treatment of gastric and duodenal fistulas*. Surg Clin North Am, 1996. 76(5): p. 1137-46.
- [51] Schirmer, C. C., et al., *Alternative surgical treatment for complex enterocutaneous fistula*. Int Surg, 1999. 84(1): p. 29-34.

