

## Chapter 2

### Esophageal Fistulas

Nadim al Hajjar

Radu Urs

Emil Mois

Cosmin Caraiani

Cristian Tefas

Marcel Tantau

Florin Graur



## Introduction

Esophageal fistula is a major surgical complication associated with esophageal resection. It has the potential to be a life threatening and fatal complication.

It is well known that in the past, anastomotic leakage was one of the most important causes of postoperative mortality after esophagectomy interventions. In recent years, due to new developments in anastomotic technique, patient selection and careful perioperative management the impact of an anastomotic leak is less severe. The incidence of anastomotic complications and treatment options are closely related to the methods of esophageal resection and reconstruction [1].

In recent literature, anastomotic leak rates can be as high as 21% [2]. This type of early complication is among the main causes of postoperative mortality and is estimated to be involved in up to 90% of deaths following esophagectomy [3]. Anastomotic leaks are generally less common than respiratory complications but their impact on the outcome is often more severe.

Early recognition of the sign and symptoms associated with esophageal fistula and immediate specific treatment is needed to prevent the development of potentially fatal complications.

## Classification

**Table 1.** *Classification of esophageal anastomotic leaks, based on Lerut et al.*

Type of leak	Definition	Treatment
Radiological	No clinical signs present	No supplementary treatment needed
Clinical minor	Local inflammation of cervical wound, fever, elevated WBC	The wound must be drained, withhold oral intake, antibiotics
Clinical major	Severe anastomotic disruption on endoscopy, sepsis, shock	Interventional imaging treatment, surgical reintervention
Conduit necrosis	Needs endoscopic confirmation	Surgical reintervention

For a long period, the definition of anastomotic leaks was not clear. This caused wide variations in the incidence of anastomotic leak. The definition included the flow of gastric fluid from chest tubes, outflow of saliva from the cervical wound, pleural or mediastinal infections, septicemia, empyema and pneumothorax. The definition has become clearer after Lerut graded anastomotic leaks in 2002 [1] (Table 1). He divided fistulas in four categories, based on their clinical impact. The first type, the *radiological leak* was defined as a leak diagnosed only after radiographic water soluble contrast study was performed, with no clinical signs and no required treatment. A *clinical minor* leak requires the presence of local inflammation of the cervical wound, fever, elevated white blood count and is managed by cervical wound drainage, delayed oral intake and use of broad spectrum antibiotics. The third type of leak, *clinical major*, was defined by severe disruption of anastomosis on endoscopy managed by CT-guided drainage or reintervention. *Conduit necrosis* requires endoscopic confirmation and the treatment consists of reintervention with conduit resection and cervical esophagostomy.

## **Etiology and Risk Factors**

Many factors contribute to the process of wound healing and are directly and indirectly linked to anastomotic leak occurrence. These factors can be divided into two categories, local and systemic.

Local factors refer mostly to the esophagus and the conduit. The esophagus is distinct from other gastrointestinal organs by the fact that it has no serosa, the muscular layer is primarily made of longitudinal muscle fibers and it has a poor blood supply. These factors make the esophagus susceptible to longitudinal tearing and highly sensitive to anastomotic tension. Gastric conduit distention and a tight thoracic inlet can also contribute to anastomotic leak formation. Another important local factor is the adequate vascular supply of the gastric, colic or small

intestine conduit. Vascular insufficiency is associated with anastomotic leak and conduit necrosis. Preoperative radiotherapy is also a factor to be considered [4].

Systemic factors include poor nutrition, low levels of serum albumin, cardiopulmonary disease and diabetes. Often patients present themselves with dysphagia as the first sign of disease, in many instances with a poor nutritional status.

Iatrogenic perforation during endoscopic procedures, although rare, must be considered. The endoscopic procedures with the highest risk of perforations are endoscopic mucosal resection, endoscopic submucosal dissection, peroral endoscopic myotomy, as well as procedures used to dilate strictures or remove tumor growths.

## Prevention

General parameters such as hemoglobin and serum albumin levels must be corrected before surgery. Adequate nutrition must be insured, by IV supplements or by jejunostomy feeding if deemed necessary.

High blood loss during surgery was found to be a risk factor in developing anastomotic fistula. Dewar et al. found a significant correlation between low serum albumin, high intraoperative blood loss and anastomotic leak [5].

Choosing the conduit is a very important step. Jejunum is rarely used because it is technically more difficult to prepare and often it is difficult to obtain a long enough loop to reach the neck for anastomosis. This can result in longitudinal tension through the loop, affecting blood supply and increasing the risk of anastomotic fistula. The colon has a good vascular anatomy, vascular arcades connecting the right, middle and left colic arteries providing good blood supply. The stomach remains the most preferred organ to restore continuity mainly because it is easy to prepare and only one anastomosis is required. The entire

vascularization depends on the right gastroepiploic artery and vein, providing good vascularization for the distal two thirds of the conduit while the proximal one third is vascularized through a microvascular and submucosal network [6]. It is very important to avoid trauma or rough handling of the conduit during dissection, preparation, gastric pull up maneuver and anastomosis [7]. Kocher maneuver is recommended in case of tension through the gastric conduit.

A good nutrition regimen before and after the surgery is very important in reducing the risk of fistula. Naso-duodenal feeding tube and jejunostomy are recommended to ensure good nutritional intake postoperatively.

Birkmeyer et al. showed that both hospital and surgeon volume remain independent predictors of operative mortality. Inexperienced and low volume doctors and hospitals can have a rate of complications and mortality two times greater than experienced teams and high volume centers [8].

## **Clinical Presentation and Diagnosis**

Almost a third of the patients presenting anastomotic leakage can be asymptomatic at the moment of diagnosis. The symptoms differ with the localization of the leak. Patients with cervical leaks present with fever, elevated white blood cell count, saliva in the wound or drained by the cervical drainage, erythema. Usually the leak is evident from 5 to 10 days post-op.

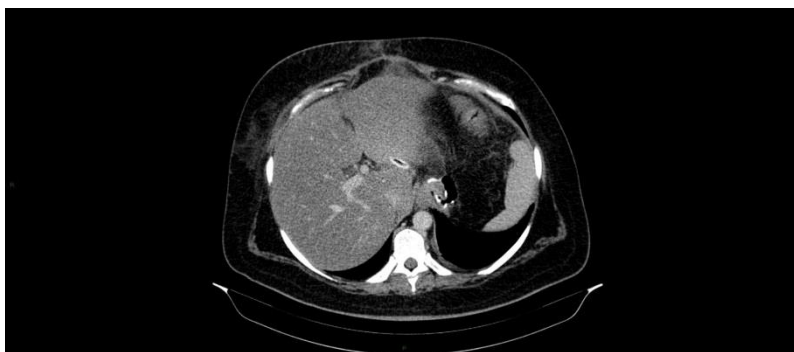Patients with intrathoracic leaks can present fever, leukocytosis, malaise, pleural effusion, shortness of breath, dysrhythmias, chest pain, bilious drainage from the chest tube. The onset may be insidious. If the leak is not properly drained, patients can develop intrathoracic collection, increasing the risk of fistula development in nearby organs like the pleura, airways and even the large intrathoracic blood vessels.

The symptoms and signs stated above correspond to radiological, clinical

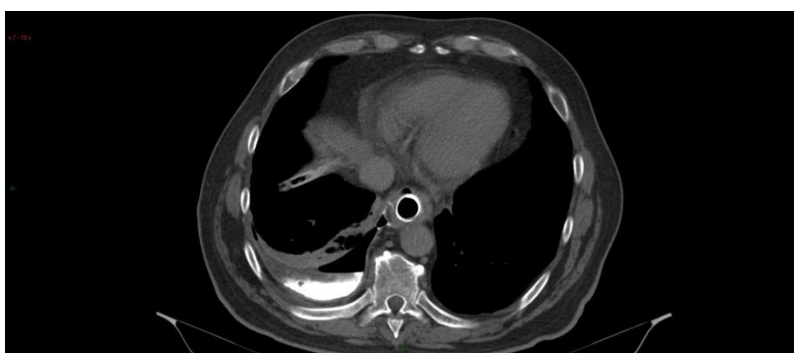minor and major leaks. A fulminant leak corresponds to conduit necrosis or technical error. It is usually evident in the first 48 to 72 hours post-op. Patients present systemic sepsis, empyema, purulent drainage and mediastinal collection.

Anastomotic leak is a major complication of esophagectomy with a relatively high reported mortality of 3,3% [9]. They either occur early because of poor technique or late (days 5 to 7) when their cause is local ischemia [10]. In half of instances they can be asymptomatic and their diagnosis is incidental following esophageal imaging with orally administered contrast solutions at 7 days postoperative. The most widely used imaging method for detecting esophageal leaks is radiological examination of the esophagus with per-orally administered hyper dense and hydrosoluble contrast. With this examination, the leak is evident when contrast solution is seen outside the esophagus and the conduit. During the examination, the patient must change position multiple times to correctly assess the leak. The trajectory of the contrast solution must be described as well as fistulous paths with nearby structures, most commonly the bronchia and pleura [11] The radiologic assessment will influence the treatment path. Contained leaks have a small output and they can be managed conservatively. Patient with major leaks develop mediastinal collections that need to be drained. Major esophago-pleural and esophago-bronchial leaks benefit from surgical reintervention. With superior accuracy in describing the trajectory of the leak and the size of intrathoracic collection, computed tomography with orally administered hyper dense contrast is shaping to be the next gold standard in evaluating esophageal leaks. From a technical standpoint, the computed tomography for esophageal leaks consist of three different scans. The first examination is native, without contrast. Then, the contrast is administered per orally before the second examination. Careful comparison between native and contrast images is needed to highlight the leak. Contrast solution leaks can be mistaken for mediastinal lymphadenopathy calcification or

residual contrast solution from prior examinations. The third scan is done with intravenous contrast to better evaluate the surrounding affected tissue and organs and to correctly measure the size of mediastinal collections (Figure 1; Figure 2; Figure 3; Figure 4). Strauss et al. have shown that computer tomography with oral contrast and computed tomography of mediastinal air improve the sensitivity and negative predictive value for diagnosing an anastomotic leak. These types of examinations are usually performed at six or seven days postoperative and can be repeated if signs and symptoms persist or are evident after the initial examination [12].

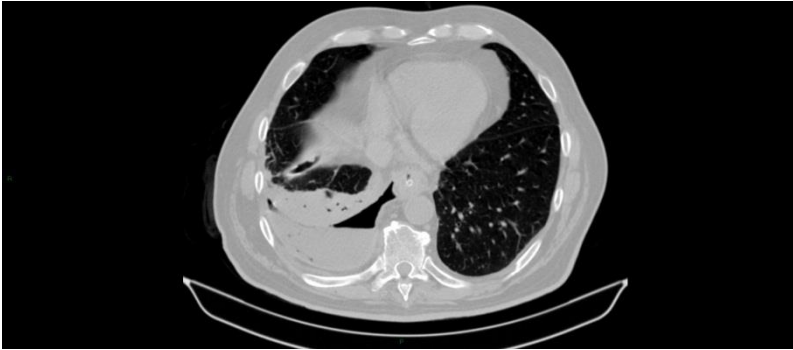


**Figure 1.** *Esophagogastric anastomosis fistula (blind) - without fluid collection or communication with other organs.*

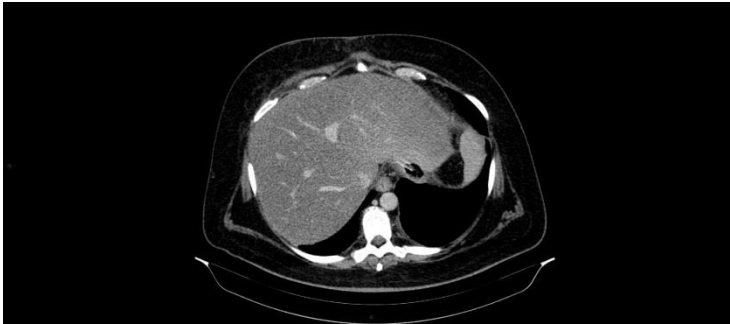

**Figure 2.** *Esophagogastric anastomosis fistula - communicating with a pleural fluid collection in the right. Oral contrast flows into a right pleural collection with gas and liquid content.*

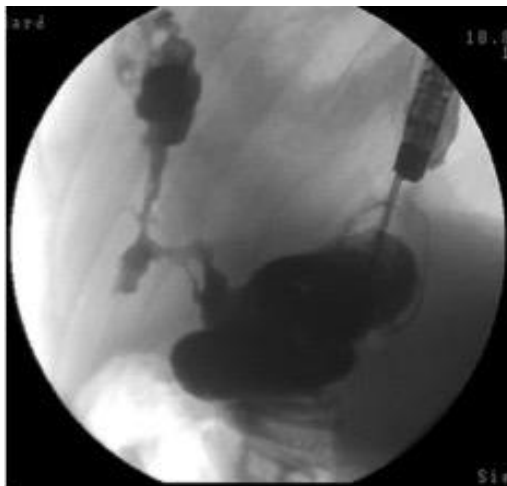




**Figure 3.** Esophagogastric anastomosis fistula as an aeric tract in pulmonary window.



**Figure 4.** Esophagogastric anastomosis fistula with the drain in the fistulous tract.



**Figure 5.** Esojejunal fistula - Endoscopic contrast injection showing a fistula after gastric resection with esophageal anastomosis.

In the case of clinical major leaks or conduit necrosis, flexible esophagoscopy can evaluate the conduit for vascular insufficiency or necrosis (Figure 5). The mucosa is often suffering but this does not prove full thickness necrosis of the conduit.

## **Treatment**

There are multiple avenues of approach which involve conservative treatment, endoscopic, interventional imaging and surgical treatment. An experienced medical and surgical team is needed to assess the severity of the leak, the general condition of the patient and the clinical and paraclinical parameters to ensure the best approach.

### **Conservative Treatment**

The non-operative approach to esophageal leaks has evolved rapidly in the last years. Important to the non-operative management is careful case selection. Appropriate patient selection can lead to survival rates close to 100 percent. To achieve this, careful patient monitoring by experienced clinical and surgical teams is needed. Leaks located in the cervical area are best suited for the non-operative approach due to the anatomic confinement of the esophagus and/or conduit by surrounding anatomical structures.

In current literature, the non-operative approach is recommended for patients with early diagnosis, with strong evidence that the leak is small and contained with minimal extraluminal spilling. Conservative treatment consists of withholding oral intake, supplemental intravenous nutrition, broad spectrum antibiotics, high protein enteral feeding through the jejunostomy tube if present and chest physiotherapy. Nasogastric suction and persistent chest drainage is often required. Adequate thoracic drainage is needed to keep the lungs expanded to avoid pulmonary complications. Radiologic examination with per oral

contrast must be repeated at 1 week or at intervals if the leak is still present. Oral intake must be resumed gradually if the leak decreased or is resolved [13].

## **Endoscopic Treatment**

Esophageal fistulae and leaks are mostly encountered after surgery, but they can also result from endoscopic procedures, as well as spontaneously (Boerhaave syndrome). The endoscopic procedures with the highest risk of perforations are endoscopic mucosal resection (EMR), endoscopic submucosal dissection (ESD), peroral endoscopic myotomy (POEM), as well as procedures used to dilate strictures or remove tumoral growths. Patients with esophageal fistulae used to be treated exclusively by surgery, but with a poor prognosis due to the fact that they may already have concurrent infection or nutritional deficiency. Thus, a series of endoscopic treatment alternatives have been introduced over the past few years, proving that they are safe and effective.

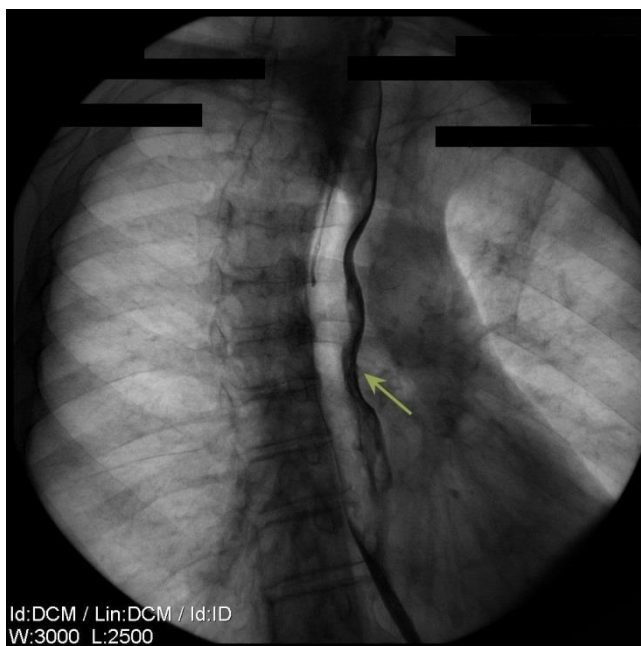The preferred endoscopic technique for treating esophageal leaks and fistulae is chosen taking into account their site and size. The use of endoscopic treatments may be difficult in the proximal part of the esophagus, due to limited space and patient tolerance. Regarding size of the perforation, smaller ones (under 2 cm) can be closed using endoscopic clips, while larger defects (over 2 cm) may be managed using stents or endoscopic suturing.

A special consideration has to be given to endoscopic insufflation. During the endoscopic procedure, carbon dioxide insufflation is preferred, as it has a rapid systemic absorption in the eventuality of a gas leak in a body cavity. Using CO<sub>2</sub> has been shown to result in less pain, less need for sedatives and more procedural flexibility.

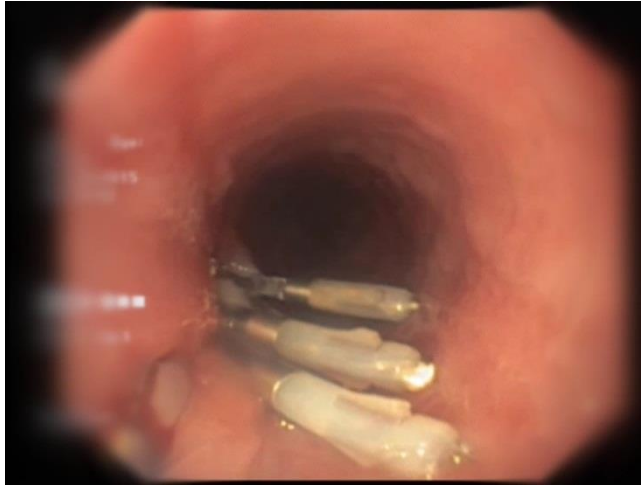To confirm the effectiveness in closing the defects, all patients should undergo a contrast study or other imaging studies after endoscopic treatment.

## Endoclips

Endoscopic clips may either be through-the-scope (TTS), when they are inserted through the endoscopic operating channel, or over the scope (OTS) when they are fixed on a device located at the distal end of the endoscope. Endoclips were originally used to treat digestive bleeding, but now their applicability has expanded formidably. As such, they are used for marking lesions for subsequent surgical removal, anchoring feeding tubes into place, closure of parietal defects after endoscopic mucosal resection (EMR) or endoscopic submucosal dissection (ESD) or for treatment of digestive fistulae of various etiologies (Figure 6; Figure 7).



**Figure 6.** Esobronchial fistula. Esophagogram at one month after the endoscopic fistula closure. Arrow points to where the diverticular fistula was, with no extravasation of contrast agent. A remaining endoscopic clip can also be seen.



**Figure 7.** *Esobronchial fistula. Endoscopic clips used to close the esobronchial fistula.*

TTS clips exist in various forms and, depending on the manufacturer, may have two or three prongs of different lengths and with different angulations. Some are preloaded while others are rechargeable. Some clips can be rotated, but once deployed cannot be repositioned, while others don't allow rotation, but can close and open repeatedly, allowing optimal positioning.

TTS clips are useful when the parietal defect is small, less than 1 cm and are preferred when it is located in the cervical esophagus, where stents can cause complications. Some authors recommend that mucosal incisions be made before clipping on the edge of the lesion, making it “raw”, as these incisions would favor scarring by formation of granulation tissue [14].

When the lesion is identified, the endoclip is advanced through the working channel of the endoscope until the sheathed clip is visible. The clip is “armed”, unsheathing it by retraction at the handle, positioned, and then “fired”.

If the defect is larger than 20-30 mm, OTS (Ovesco, Ovesco Endoscopy AG) clips are preferred. These clips, which resemble a bear claw, are larger in size and more powerful than TTS clips and thus cannot be advanced through the working channel of the endoscope but instead are mounted on a transparent cap

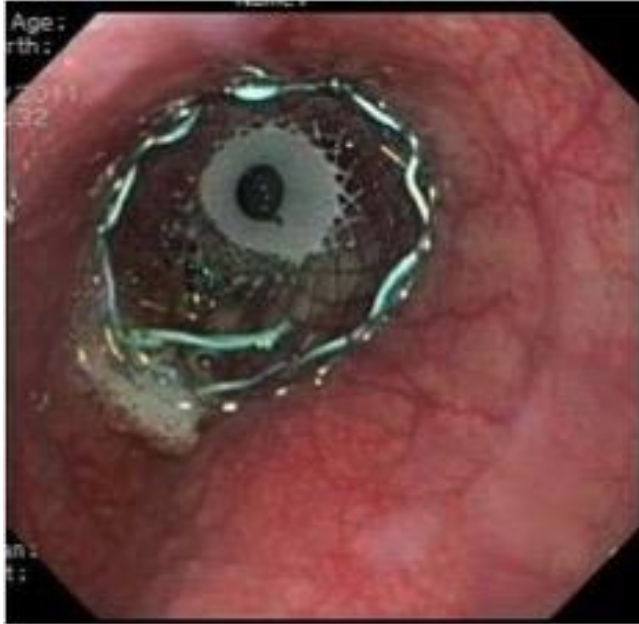secured to the endoscopic tip, with a deployment mechanism similar to that used in band ligators.

Ovesco clips come with three different sizes of caps, suitable for almost all commercially available endoscopes (11, 12 and 14 mm), as well as two different depths of caps for grasping more or less tissue (3 and 6 mm). There are also three different clip tooth shapes suitable for different indications and tissues: (t) traumatic, more frequently used to close fistulas and perforations, (a) atraumatic, used primarily to stop bleeding and (gc) gastrostomy closure [15].

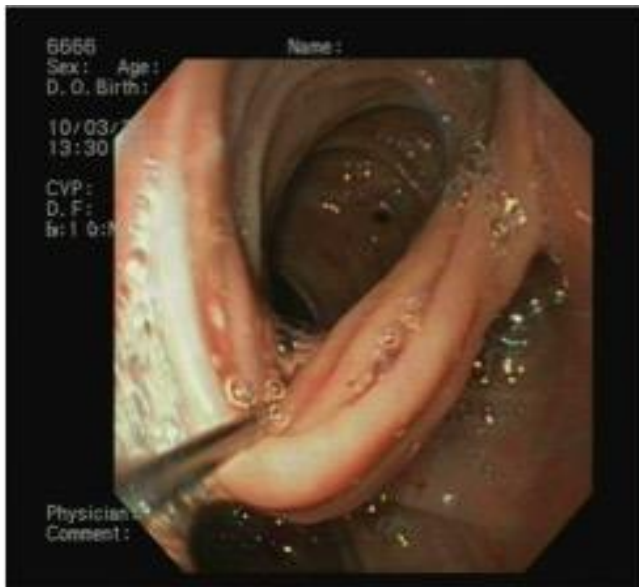When the lesion is identified, the cap is placed over it and suction is applied so that the edges of the defect are aspirated inside the cap. Dedicated accessories can help in difficult cases, such as indurated lesions: the OTSC Anchor and the OTSC Twin Grasper. Once satisfactory tissue aspiration has been achieved, the OTSC is deployed. In a recent European multicenter prospective cohort study of patients with iatrogenic perforations, 89% of patients had successful closures without adverse events after OTSC application [16].

## **Stenting**

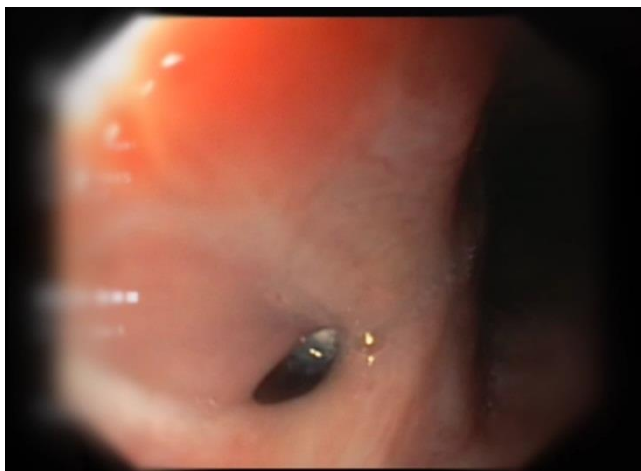
Self-expanding metal stents (SEMS) are tubular structures of various sizes and shapes, made of a metal cross-hatched mesh, with multiple applications in digestive endoscopy (Figure 8; Figure 9; Figure 10; Figure 11; Figure 12; Figure 13). They are made of Nitinol®, a biocompatible Nickel-Titanium alloy, which prevents development of rust and allows for potential magnetic resonance studies. Once deployed, they develop constant radial force under body temperature to gradually expand and remain open after placement. Stent ends are shaped with no sharp or pointed edges, in order to minimize tissue injury and are equipped with radiopaque markers.




**Figure 8.** Esojejunal fistula - Fully deployed metal stent used to cover the fistula.



**Figure 9.** Esojejunal fistula. Endoscopic guidewire in place.




**Figure 10.** *Eso-bronchial fistula. Upper esophageal diverticulum in an elder patient, with an esobronchial fistula arising from its apex.*



**Figure 11.** *Different types of esophageal metallic stents. The first two from the left are fully covered ones, while the one on the right is a partially covered stent.*





**Figure 12.** Endoscopic view of fully expanded Polyflex (Boston Scientific) plastic stent used to cover an esophageal fistula.



**Figure 13.** Fully covered plastic stent.

There are several types of metal stents, depending on their construction: covered, partially covered or uncovered, the first two being used successfully in the treatment of esophageal fistulae. In covered stents, the coating consists of Silicone, which gives the stent high elasticity. A recent pooled analysis of the literature showed that the overall clinical success rate of SEMS in the management of benign esophageal leaks was 73-78%, with a higher success in postsurgical leaks and a lower one in benign fistulae [17].

Also, to be mentioned are self-expanding plastic stents (SEPS), made of polyester braid completely covered in silicone membrane, with the proximal end flared to prevent dislocation. The plastic stents overcome some of the disadvantages associated with metal stents, allowing an easier extraction and a reduction in migration, due to their shape. There have been numerous studies conducted using plastic stents in the management of esophageal leaks, showing a success rate of 80-100% [18].

Stents can be placed either endoscopically or radiologically. Once the fistula has been identified, a guide wire is inserted and then the stent is advanced into position over it. Stents should be deployed carefully, avoiding the upper esophageal sphincter and impaction into the gastric or enteral wall.

In patients with esophageal fistulae, fully or partially covered stents should be used, positioned so as to completely cover the parietal defect. Thus, after stent placement, patients may resume oral feeding. For fistulae located in the proximal esophagus, smaller diameter stents (18-23 mm) should be used to prevent compression of adjacent structures. The medium and distal part of the esophagus allow for use of larger diameter stents (21-25 mm) [15]. In order to prevent excessive tissue in- and overgrowth, stents should be removed 6 to 10 weeks after treatment.

The major advantage of stent placement is the immediate control of leaks, protection of the esophageal wall during mucosal healing, possibility of early

oral feeding and prevention of stricture formation [19]. The major disadvantage is the risk of migration of covered stents in the absence of an underlying stenosis. Partially covered stents have a lower tendency to migrate than fully covered ones, but there is a risk of tissue in- or overgrowth, limiting the extraction of the stent. In this case, argon plasma coagulation can be used to try and dislodge the stent. Others have recommended placing a plastic stent inside the metal one for 1-3 weeks, leading to compression and necrosis of the hypertrophic tissue and easier subsequent removal [20]. The risk of migration can be reduced by using stents with a large diameter or by clipping the proximal end of the stent, thus anchoring it to the esophageal mucosa.

Another point to be considered when using stents is the presence of infection in the peri-esophageal cavity, as the implantation of a fully covered stent may prevent an adequate drainage and lead to sepsis. Hence, in such cases, stents should only be used in conjunction with percutaneous drainage.

It seems there are some other factors as well to be taken into consideration when placing esophageal stents. As such, if the leak is located in the proximal esophagus, extends for more than 6 cm or is traversing the gastroesophageal junction, treatment effectiveness is reduced.

Other complications of stent placement include pain, occlusion and bleeding. Esophageal stents may lead to perforation or formation of a tracheoesophageal fistula. Reflux, especially if placed at the gastroesophageal junction and possible subsequent aspiration can also appear.

## **Endoscopic Suturing**

Endoscopic suturing is a laborious and complex procedure with poor past results in closing digestive tract leaks and fistulae. However, the new generation of suturing devices is very promising. This device is loaded on the distal end of an endoscope and allows continuous or interrupted stitches to be made. Some of the

advantages of the technique are that it allows recharging of the thread without the need for removal of the endoscope from the body, and that by using an endoscope with a dual channel, other instruments can be advanced through one of the channels, such as a grasping forceps, for better tissue apposition. There is a plethora of potential applications for this device, ranging from perforation closure to ESD/EMR closure and stent fixation, with very encouraging results [21-23]. The major drawback of this system is that it requires a double working channel gastroscope, which limits flexibility and length of insertion thus making suturing in difficult or deep locations difficult or impossible [24].

## **Tissue Sealants**

Tissue sealants are strong, fast-acting adhesives that turn into a solid state once in contact with tissue. The most frequent used ones are fibrin glue and cyanoacrylates. Fibrin glue has fibrinogen reconstituted with aprotinin and thrombin reconstituted with calcium chloride as its main components. After being injected through a double lumen catheter it solidifies in 1-3 minutes, in a process similar to in vivo blood coagulation. Fibrin glue should be applied on dry tissue, as it is more effective. Favorable results were obtained in several studies, with successful fistula sealing rates ranging between 37% and 87% [25-27].

Cyanoacrylates are compounds with hemostatic, adhesive, sealer and bacteriostatic properties. When used in a moist environment, they polymerize in a matter of seconds into a thin elastic film, which has high tensile strength, and strongly adhere to the tissue on which they are applied. They are used in the treatment of gastric varices, but many studies have shown promising results in the treatment of esophageal fistulae [28, 29]. After injection, Lipiodol is used to flush the remaining glue from the catheter, in order to avoid polymerization over the distal end of the endoscope, and thus damage to the lens.

To promote healing of the fistula, the mucosa around the opening should be

traumatized using argon plasma coagulation, thus promoting inflammation and formation of granulation tissue. The major drawback of both fibrin glue and cyanoacrylates is that one treatment session is usually not enough to fully close parietal defects. In this sense, combination therapy using other endoscopic treatment can be applied (clips, stenting, Vicryl mesh) [30].

## **Endoscopic Vacuum Assisted Closure (EVAC)**

Endoscopic vacuum therapy has been proven to be a viable alternative in patients with esophageal leakages, in whom other endoscopic or surgical treatments have failed. A sponge that has been connected to a drainage tube is endoscopically inserted in the periesophageal cavity. The sponge induces granulation tissue formation, while the drainage tube allows for continuous vacuum at a pressure of 125 mmHg, resulting in wound secretion removal and reduction of edema. The size of the sponge is adapted to the size of the cavity and is changed every 2-3 days. Treatment lasts for a median of 29 days [31]. Once the sponge is completely removed, the remaining small cavity heals spontaneously.

## **Cardiac Septal Defect Occluder**

The Amplatzer Septal Occluder Device (AGA Medical Group), is a device used to treat structural heart disease (i.e. atrial septal defect), consisting of two self-expandable disks made of Nitinol® mesh covered by polyester fabric, connected by a short waist [2]. The central waist diameter ranges from 4 to 40 mm, and the respective distal and proximal disk diameters are 14 and 10 mm. It is very important to match the correct diameter to the size of the fistula, as choosing a wrong size may enlarge the fistula. There have been a few reports showing good results in the management of tracheoesophageal fistulae using this device [32, 33].

## **Interventional Imaging Treatment**

Computed tomography guided drainage is a viable option of treatment for intrathoracic leaks. It allows the safe placement of tubes and efficient drainage of mediastinal abscesses and leaks. Recent studies have shown that it is associated with high clinical success and low risks for patients [34]. Its usage is reserved in cases where a clinical major leak and mediastinal abscess is present, with a viable gastric conduit. Often, efficient drainage of the abscess and the mediastinal space is sufficient. A major advantage over surgery is the fact that it can be repeated if necessary with no major risk of added morbidity or mortality.

## **Surgical Treatment**

Post esophagectomy anastomotic leaks infrequently require surgical treatment. Endoscopic and interventional imaging treatment are the preferred minimally invasive treatment options. Reinterventions are associated with a high mortality rate, up to 25%, but overall 5-year survival does not seem to be influenced by the reintervention rate [35].

Reintervention is required for clinically major leaks when endoscopic and interventional imaging techniques fail to contain the leak. Often patients develop hydro-pneumothorax, sepsis and shock, requiring emergency exploration. The intervention consists of rapid evacuation of the mediastinal collection and proper drainage. In case of a viable conduit, debridement of the anastomosis with primary closure is a viable option. If the conduit necrosis is limited to the proximal segment, the resection of the necrotic section with primary re-anastomosis is possible.

Extensive conduit necrosis requires removal of the affected section and the creation of a cervical esophagostomy. At a later stage, colonic or jejunal reconstruction must be considered if the patient survives this severe complication. Very important to the success of the reoperation and survivability

is early reintervention, with majority of the patients set to recover if surgery is undertaken early [36].

The incidence of anastomotic complications and the surgical treatment necessary are closely related to the methods of esophageal resection and reconstruction. The standard surgical approaches for adenocarcinoma and squamous carcinoma located in the lower esophagus are left thoraco-abdominal, Ivor-Lewis/Tanner and transhiatal. For lesions in the mid third of the esophagus, the majority being squamous carcinoma and rarely adenocarcinoma, the preferred surgical approaches are high Ivor-Lewis/Tanner, three stage total esophagectomy and transhiatalesophagectomy. In current literature, reintervention rates are higher for fistulas of the intra-thoracic anastomosis than cervical anastomosis mainly because cervical leaks tend to be of the radiological or clinical minor type. Video-assisted thoracoscopy tend to become the gold standard for esophagectomy approach.

## Conclusion

In recent years, esophageal cancer incidence in the developed countries is on the rise. Surgical resection coupled with chemotherapy and/or radiotherapy is the gold standard of treatment for about 50% of the patients. The rest benefit from palliative techniques and treatments such as endoscopic stenting. Given the low survivability of around 20% at 5 years even with potentially resectable disease, low morbidity and mortality rates after esophagectomy are essential. Anastomotic leak is a major complication following resection and it is estimated to be involved in up to 90% of deaths following esophagectomy. Lately, a better understanding of the systemic and local factors that contribute to anastomotic leak formation allowed for a steady decline of incidence. Early diagnosis coupled with new minimally invasive treatment option such as endoscopic closure and radiologically guided treatments has steadily improved the mortality

associated with this type of postoperative complication. Surgery remains the standard treatment for clinically major leaks and conduit necrosis [37].

Recent studies have shown that both hospital and surgeon volume are important independent predictors of operative mortality. Experienced centers and surgeons report operative mortality two times lower than low volume and low experience teams [38]. This type of surgical intervention must be performed in high volume centers by highly experienced teams of surgeons and physicians with access to modern endoscopic and interventional imaging treatment options.

## References

- [1] Lerut T, Coosemans W, Decker G, De Leyn P, Nafteux P, van Raemdonck D. Anastomotic complications after esophagectomy. *Digestive surgery*. 2002; 19(2): 92-8.
- [2] Tabatabai A, Hashemi M, Mohajeri G, Ahmadinejad M, Khan IA, Haghdani S. Incidence and risk factors predisposing anastomotic leak after transhiatal esophagectomy. *Annals of thoracic medicine*. 2009; 4(4): 197-200.
- [3] Kim RH, Takabe K. Methods of esophagogastric anastomoses following esophagectomy for cancer: A systematic review. *Journal of surgical oncology*. 2010; 101(6): 527-33.
- [4] Briel JW, Tamhankar AP, Hagen JA, DeMeester SR, Johansson J, Choustoulakis E, et al. Prevalence and risk factors for ischemia, leak, and stricture of esophageal anastomosis: gastric pull-up versus colon interposition. *Journal of the American College of Surgeons*. 2004; 198(4): 536-41; discussion 41-2.
- [5] Dewar L, Gelfand G, Finley RJ, Evans K, Inculet R, Nelems B. Factors affecting cervical anastomotic leak and stricture formation following esophagogastrectomy and gastric tube interposition. *American journal of surgery*. 1992; 163(5): 484-9.
- [6] Sharma S. Management of Complications of Radical Esophagectomy. *Indian Journal of Surgical Oncology*. 2013; 4(2): 105-11.
- [7] Chen K-N. Managing complications I: leaks, strictures, emptying, reflux, chylothorax. *Journal of Thoracic Disease*. 2014; 6(Suppl 3): S355-S63.



- [8] Birkmeyer JD, Stukel TA, Siewers AE, Goodney PP, Wennberg DE, Lucas FL. Surgeon volume and operative mortality in the United States. *The New England journal of medicine*. 2003; 349(22): 2117-27.
- [9] Martin LW, Swisher SG, Hofstetter W, Correa AM, Mehran RJ, Rice DC, et al. Intrathoracic Leaks Following Esophagectomy Are No Longer Associated With Increased Mortality. *Annals of Surgery*. 2005; 242(3): 392-402.
- [10] Lerut T, Coosemans W, Decker G, De Leyn P, Moons J, Naftoux P, et al. Surgical techniques. *Journal of surgical oncology*. 2005; 92(3): 218-29.
- [11] Urschel JD. Esophagogastrostomy anastomotic leaks complicating esophagectomy: a review. *American journal of surgery*. 1995; 169(6): 634-40.
- [12] Strauss C, Mal F, Perniceni T, Bouzar N, Lenoir S, Gayet B, et al. Computed tomography versus water-soluble contrast swallow in the detection of intrathoracic anastomotic leak complicating esophagogastrrectomy (Ivor Lewis): a prospective study in 97 patients. *Ann Surg*. 2010; 251(4): 647-51.
- [13] Brinster CJ, Singhal S, Lee L, Marshall MB, Kaiser LR, Kucharczuk JC. Evolving options in the management of esophageal perforation. *The Annals of thoracic surgery*. 2004; 77(4): 1475-83.
- [14] Tantau M, Visovan I, Tefas C. Endoscopic closure of spontaneous idiopathic esophagobronchial fistula. *Gastrointestinal endoscopy*. 2016; 84(5): 847-8.
- [15] Rogalski P, Daniluk J, Baniukiewicz A, Wroblewski E, Dabrowski A. Endoscopic management of gastrointestinal perforations, leaks and fistulas. *World journal of gastroenterology*. 2015; 21(37): 10542-52.
- [16] Voermans RP, Le Moine O, von Renteln D, Ponchon T, Giovannini M, Bruno M, et al. Efficacy of endoscopic closure of acute perforations of the gastrointestinal tract. *Clinical gastroenterology and hepatology: the official clinical practice journal of the American Gastroenterological Association*. 2012; 10(6): 603-8.
- [17] van Halsema EE, van Hooft JE. Clinical outcomes of self-expandable stent placement for benign esophageal diseases: A pooled analysis of the literature. *World journal of gastrointestinal endoscopy*. 2015; 7(2): 135-53.
- [18] Moyes LH, MacKay CK, Forshaw MJ. The Use of Self-Expanding Plastic Stents in the Management of Oesophageal Leaks and Spontaneous Oesophageal Perforations. *Diagnostic and Therapeutic Endoscopy*. 2011; 2011.

- [19] van Boeckel PG, Dua KS, Weusten BL, Schmits RJ, Surapaneni N, Timmer R, et al. Fully covered self-expandable metal stents (SEMS), partially covered SEMS and self-expandable plastic stents for the treatment of benign esophageal ruptures and anastomotic leaks. *BMC Gastroenterology*. 2012; 12(1): 19.
- [20] Eisendrath P, Cremer M, Himpens J, Cadiere GB, Le Moine O, Deviere J. Endotherapy including temporary stenting of fistulas of the upper gastrointestinal tract after laparoscopic bariatric surgery. *Endoscopy*. 2007; 39(7): 625-30.
- [21] Bonin EA, Wong Kee Song LM, Gostout ZS, Bingener J, Gostout CJ. Closure of a persistent esophagopleural fistula assisted by a novel endoscopic suturing system. *Endoscopy*. 2012; 44 Suppl 2 UCTN: E8-9.
- [22] Kantsevoy SV, Bitner M, Mitrov AA, Thuluvath PJ. Endoscopic suturing closure of large mucosal defects after endoscopic submucosal dissection is technically feasible, fast, and eliminates the need for hospitalization (with videos). *Gastrointestinal endoscopy*. 2014; 79(3): 503-7.
- [23] Kantsevoy SV, Thuluvath PJ. Successful closure of a chronic refractory gastrocutaneous fistula with a new endoscopic suturing device (with video). *Gastrointestinal endoscopy*. 2012; 75(3): 688-90.
- [24] Stavropoulos SN, Modayil R, Friedel D. Current applications of endoscopic suturing. *World journal of gastrointestinal endoscopy*. 2015; 7(8): 777-89.
- [25] Lippert E, Klebl FH, Schweller F, Ott C, Gelbmann CM, Scholmerich J, et al. Fibrin glue in the endoscopic treatment of fistulae and anastomotic leakages of the gastrointestinal tract. *International journal of colorectal disease*. 2011; 26(3): 303-11.
- [26] Kotzampassi K, Eleftheriadis E. Tissue sealants in endoscopic applications for anastomotic leakage during a 25-year period. *Surgery*. 2015; 157(1): 79-86.
- [27] Rabago LR, Ventosa N, Castro JL, Marco J, Herrera N, Gea F. Endoscopic treatment of postoperative fistulas resistant to conservative management using biological fibrin glue. *Endoscopy*. 2002; 34(8): 632-8.
- [28] Pramateftakis M-G, Vrakas G, Kanellos I, Mantzoros I, Angelopoulos S, Eleftheriades E, et al. Endoscopic application of n-butyl-2-cyanoacrylate on esophagojejunal anastomotic leak: a case report. *Journal of Medical Case Reports*. 2011; 5: 96.

- [29] Saikia MK, Kalita JP, Handique A, Topno N, Sarma K. Bronchoesophageal Fistula Repair with Intercostal Muscle Flap Followed by Occlusion of Residual Diverticula with N-butyl Cyanoacrylate (NBCA) Glue: A Case Report. *Journal of clinical and diagnostic research: JCDR*. 2016; 10(8): Pd03-4.
- [30] Bohm G, Mossdorf A, Klink C, Klinge U, Jansen M, Schumpelick V, et al. Treatment algorithm for postoperative upper gastrointestinal fistulas and leaks using combined vicryl plug and fibrin glue. *Endoscopy*. 2010; 42(7): 599-602.
- [31] Lenzen H, Negm AA, Erichsen TJ, Manns MP, Wedemeyer J, Lankisch TO. Successful treatment of cervical esophageal leakage by endoscopic-vacuum assisted closure therapy. *World journal of gastrointestinal endoscopy*. 2013; 5(7): 340-5.
- [32] Cohen-Atsmoni S, Tamir A, Avni Y, Priel IE, Roth Y. Endoscopic Occlusion of Tracheoesophageal Fistula in Ventilated Patients Using an Amplatzer Septal Occluder. *Indian journal of otolaryngology and head and neck surgery: official publication of the Association of Otolaryngologists of India*. 2015; 67(2): 196-9.
- [33] Repici A, Presbitero P, Carlino A, Strangio G, Rando G, Pagano N, et al. First human case of esophagus-tracheal fistula closure by using a cardiac septal occluder (with video). *Gastrointestinal endoscopy*. 2010; 71(4): 867-9.
- [34] Arellano RS, Gervais DA, Mueller PR. Computed tomography-guided drainage of mediastinal abscesses: clinical experience with 23 patients. *Journal of vascular and interventional radiology: JVIR*. 2011; 22(5): 673-7.
- [35] Crestanello JA, Deschamps C, Cassivi SD, Nichols FC, Allen MS, Schleck C, et al. Selective management of intrathoracic anastomotic leak after esophagectomy. *The Journal of thoracic and cardiovascular surgery*. 2005; 129(2): 254-60.
- [36] Wormuth JK, Heitmiller RF. Esophageal conduit necrosis. *Thoracic surgery clinics*. 2006; 16(1): 11-22.
- [37] Mitchell JD. Anastomotic leak after esophagectomy. *Thoracic surgery clinics*. 2006; 16(1): 1-9.
- [38] Schaheen L, Blackmon SH, Nason KS. Optimal approach to the management of intrathoracic esophageal leak following esophagectomy: a systematic review. *American journal of surgery*. 2014; 208(4): 536-43.

