

Introduction

This work is my attempt to simplify and teach basic sciences and their application in clinical decision making.

Students of surgery must know that communication skills, mannerism and ethics play a very significant role in the learning phase of their life. Any student in a white coat with a stethoscope around the neck and hammer and tuning fork peeking out of the coat pocket cannot disguise the fact that they are still students and that they have to win the trust of their patients before they can obtain the required information related to their history and physical examination.

Students must introduce themselves to their patients, take their permission, maintain privacy, and respect confidentiality of the information provided. They must keep the conversation simple, focused, specific and relevant to the patients' problems, and use uncomplicated understandable terms. Students should not independently discuss the diagnosis, prognosis and management with the patient or any member of their family. Any curiosity and questions in this respect should be directed to the treating surgeon.

There is no substitute for modest appearance and courteous behavior. Be gentle to your patients who must already be suffering. That is often why they seek medical help. While examining them do not do anything that may increase their pain or suffering. Remember the dictum: 'If you cannot do any good, please do not do any harm'.

Surgical examination includes examination of private parts and internal examinations. Seek permission before proceeding. A cooperative patient can help solve many of students' problems.

Most surgical patients have wounds that require dressings. Do not expose wounds repeatedly. Follow instructions from the teacher or the nurse. Pay attention to hygiene and patients' comforts. Wash your hands, use gloves where necessary. Do not expose or move your patient unnecessarily. Prepare a scheme for examination before you expose the patient. Thus you can complete the examination and accomplish the objectives within the shortest time and with minimal discomfort for the patient.

Finally, students should note that all major problems in general surgery can be covered in following TEN groups. Once they master the basics of these ten subjects from a book like this and the details from their text books, they would have covered almost all common general surgical conditions which they are likely to encounter in their practice. These TEN groups are:

1. General principles of surgery
2. Non-specific surgical conditions
3. Trauma
4. Abdomen: Acute abdomen and Abdominal masses
5. Ano-rectum
6. Hernias
7. Cervico-facial surgical conditions
8. Breast lumps
9. Acute chest pain and dyspnoea, of surgical origin
10. Limbs and Peripheral Vascular Diseases [including diabetic foot]

This book focuses on applied anatomy, Patho-physiology and principles of management of these ten groups, based on my experience and understanding.

General Principles of Clinical Practice

Communication Skills

Communication is an art. It cannot be taught; it must be learnt. It can only be mastered by apprenticeship.

Communication skills include:

- Communication with words
- Communication with expressions and mannerism
- Communication with documents

In verbal communications, it is important to remember that:

- Words are like arrows, once they leave the bow, they cannot be retrieved.
- Words are double edged weapons, they can heal or hurt.
- Expressions, as means of communication are as important as words. It can communicate as much as the words.
- Control of expressions while talking is part of communication skills.
- Psychological healing is as important as physical healing. Proper Communication can achieve psychological healing; and half of the battle is won.
- In medical profession communication skills have special significance since it may affect the patients and their family.

One must remember following points before starting any communication

- *What to talk*—Unlike casual conversations, communication with the patients and their families should be thought of before passing on the

message regarding illness, management and the outcome.

- *How to talk*—Messages which are conveyed to any one at any level should be logical, legitimate, relevant, precise, to the point and clear. It should not be repetitive. It should be emphatic, modest yet firm.
- *When to talk*—This decision can make a world of difference and judicious consideration is required. Certain information can wait while others may need immediate communication. Remember, ‘A stitch in time can save nine’.
- *With whom to talk*—There are two channels of communication. Vertical communication is giving instructions to the juniors, and conveying patients’ progress and related information to the seniors. Horizontal communication is with colleagues at more or less same level; resident to resident, consultant to consultant, endorsements of cases to colleagues at horizontally equal level and so on. Both require the above mentioned criteria of ‘What to talk’.
- *Where to talk*—Anything that can alarm the patient should be discussed with the team away from the patient, after the patient has left the clinic or after the rounds in wards.
- *What NOT to talk*—It is important to appreciate one’s limitations and act accordingly. Loose talks can harm and hurt patients irreversibly.

Consultant in charge or attending physician should be the only one to discuss and communicate patient’s diagnosis, prognosis, and management of the case.

One should always tell the truth. However in interest of the patients in terminal stages of disease, exceptions can be made. It is prudent to let the patient have hope and serenity of mind during the final phase of life.

However truth must be told to the family; they should not be misguided.

Professional Ethics

Privacy and confidentiality are the two vital components of professions medical ethics.

- Introduce yourself and explain your purpose.
- Pay attention to your appearance and manners.
- Do not exceed your brief and limitations.
- Choose language of communications which patient understands.
- Use translator if necessary.
- Control your expressions and do not frighten the patient and family.
- Use simple terms and avoid too many technical terms; make sure patient understands.
- Address patient's concerns and doubts and answer the questions without ambiguity.
- Give time to think and consider, do not force your opinion.
- Remember that 'Good professional practice has no relation to good clinical skills'.

Intention of every clinician is to help the patient, to manage the problems and to cure where possible. Clinical practice involves bodily examinations and invasions. These actions must always be with the 'Informed consent' of the patient or the family, as the case may be.

Invariably patients consent because they trust their physician. In procedures involving bodily invasions including surgical procedures, written informed consent must always be taken, and should be witnessed for medico-legal purposes. Be aware of yours as well Patient's rights.

Informed consent includes explanations of the following:

Why is the procedure necessary?

What type of procedure is selected?

What are the alternatives to the selected procedure?

What are expected side effects and the final outcome of the procedure?

What are the consequences of patient's refusal for the procedure?

Certain decisions in clinical practice can be very difficult, and occasionally very painful, to take. Withdrawal of life support system and certification of death can be the most painful decisions. However, once a decision is taken, be prepared to accept responsibility.

Promise of special favors, monetary or in other forms, or lack of them, should not affect your judgment. Accept acceptable returns only.

Finally, always be prepared to help. It is your legal as well as moral requirement to fulfill your Hippocrates's Oath and its Obligations!

Safety in Clinical Practice

In most of the text books on medicine nowadays, a chapter is included on 'Patient Safety'. It is true the safety of the patient is of paramount importance. However equally important is the safety of the personnel involved in health care of the patient. Hence I have revised the title in my book as 'Safety in clinical practice'.

This can be defined as 'Actions undertaken by individuals and organizations to protect health care recipients and providers from being harmed by the effects

of health care services’.

Recent studies suggest that Medical errors occur in up to 5% of hospital admissions. Almost as much as 10% of errors may lead to death. According to this estimate nearly a hundred thousand hospital deaths may occur each year as a result of medical errors.

Main causes for safety Violations are:

- Human errors, related to patients as well as the doctors, nurses and other members of their team
- Unexpected Hazards
- Environment related factors

Patient related factors include:

- Noncompliance
- Overindulgence
- Self medication
- Persistent habits
- Defiance

As for the Doctors and Nurses, such errors may occur due to:

- Ignorance
- Incompetence
- Inattention
- Negligence
- Memory lapse

- Failure to communicate
- Noisy working conditions
- Fatigue and exhaustion

It is important to remember that, because of the system of privileges, ignorance and incompetence can be the cause of errors in less than one percent of people. The other 99% are good people trying to do a good job who make very simple mistakes due to unintentional, but avoidable situations listed above.

Unexpected hazards can be due to varied reasons:

- Biomedical hazards such as Contaminations, Injections, Transfusion
- Physical hazards
- Chemical, Pharmaceutical hazards
- Electrical hazards
- Radiological hazards
- Poorly designed equipment, appliances, monitoring equipments

Common Causes of Medication Related Errors are:

- Lack of staff orientation/training
- Communication failure
- Medication storage/access problems
- Important information not available to caregivers
- Staff competency/credentialing problems
- Inadequate supervision
- Inadequate/improper labeling

- Staff distraction

Environmental factors include:

- Air pollution, contaminations
- Cross infections
- Nosocomial infections
- Patient comfort and hygiene
- Room and bathroom conditions
- Faulty appliances and aids
- Accidents, trauma, fall, etc.

In order to ensure safety during clinical practice, we must redesign our processes so that simple mistakes don't end up harming patients and care providers. Opportunities for error should be eliminated, and better safeguards should be in place to catch and correct errors before they reach the patient and the care providers.

Preventive measures

There is growing evidence that process of 'Hand Sanitisation' can prevent incidence of infections in clinical practice. Historically, all clinicians used to dip their hands in a bowl of disinfectant such as Dettol, after seeing a patient. It turned out to be that instead of preventing infections, it increased the risk for infections; reason being that the solutions and the towels used afterwards, themselves were teaming with organisms. Hence this practice was abandoned, and has been replaced by individual hand sanitisation routines. Hands should be cleaned by disinfectant lotion or spray after examining every case. Similarly 'Proper disposal of all hazardous material' can reduce the incidence of

unwanted events and contribute to the safety of all healthcare providers.

The ultimate objective is that: ‘Let there be no harm done, to any one, patient and the healthcare providers, as a result of health care service’.

General Principles of Surgery

I understand and teach the discipline of surgery in following general principles:

Principle No.1 Common things are common

Think about them first, rare ones can follow. Do not ignore the regional impact on pathologies.

Principle No. 2 Learn to classify

Sort out all the information obtained by symptoms and signs, and like a computer, put them in different folders. The folder with maximum favorable information will be the most likely diagnosis.

Principle No. 3 Learn to make a diagnosis

Objective of clinical exercise is to arrive at a diagnosis so that appropriate management can be initiated. Diagnostic exercise includes three steps:

- History
- Physical Examination and
- Investigations

Physical examination includes three steps:

- General examination

- systems examination and
- local/regional examination

History and physical examination lead to probable diagnosis and possible differential diagnosis. Third step in diagnostic process is investigations. These are chosen according to the possibilities; either to rule in and confirm or to rule out.

Principle No. 4 Add local examination of surgical lesions

In the discipline of surgery, in addition to dealing with all systems of the body, student may also have to deal with the following additional manifestations of the disease. They are:

1. Swellings, lumps and masses.
2. Wounds, ulcers, sinuses, fistulae and gangrenes.

In surgery therefore, in addition to general and systems examinations, local examination of these lesions should also be emphasized. Once the technique of local examination of the above mentioned lesions is mastered, students are already half way in making the diagnosis.

Principle No. 5 Learn and follow the 'Clinical pathways'. This is a process of exclusion and confirmation

Start with the commonest possible diagnosis for the given situation and establish it or exclude it by following the diagnostic investigations.

Following clinical pathways is like following a road map towards the destination. One landmark should guide to the other; similarly one investigative step should guide towards the next.

Following clinical pathways avoids unnecessary investigations. It also avoids

misadventures and directs the management of situation towards the best possible outcome.

Principle No. 6 Investigations

Remember, investigation is a costly business and must be chosen wisely, with discretion and justification.

Investigations can be chosen from three distinct groups.

- Laboratory investigations: examples include the spectrum of hematology, chemistry, serology and immunology; histology and special techniques of staining, histo-chemistry, electron microscopy, etc.
- Imaging techniques: examples include ultrasonography [USG], radiology, contrast studies, scans, magnetic resonance imaging, and invasive radiology. Radiological reconstructions have enhanced the scope and accuracy of diagnosis.
- Endoscopy, real as well as virtual, through practically every accessible opening into interior of the body.

Both radiology and endoscopy can be diagnostic as well as therapeutic.

Investigations are chosen from above three groups with the following objectives in mind.

These Three objectives are:

- To make a diagnosis [diagnostic].
- To see the effects of the disease on the body.
- To see the fitness of the person for any surgical intervention.

‘Routine investigations’ is a term very frequently used in clinical practice.

Their help in making the diagnosis is limited. They fulfill the third objective, that is to assess general health of vital systems of the person, and to check for common prevailing conditions in the community, such as anemia, [CBC], diabetes, [FBS], bleeding tendencies, [PT, PTT, INR], Blood group, etc., and in elderly the state of heart [ECG] and lungs [chest x-ray] as well.

For example in a case of intestinal obstruction, x-ray is required to confirm the diagnosis, CBC and serum electrolytes are required to see its effects on body, and others like blood sugar, coagulation profile, etc. to see patient's fitness for surgery as explained above.

Principle No. 7 Follow logical diagnostic steps

Based on history, physical examination and investigations, diagnosis is arrived in three steps.

- Anatomical diagnosis.

Where is the problem? Which tissue/organ/system is involved?

- Pathological diagnosis.

What is the cause of problem? Which pathological process is involved?

- Clinical diagnosis.

What is full extent, stage or status of the problem?

With these three steps of clinical reasoning complete diagnosis can be systematically arrived.

For example in cervical swelling, anatomical diagnosis may suggest lesion in thyroid or lymph nodes; pathological diagnosis may suggest inflammatory or neoplastic process as the cause. Clinical diagnosis in thyroid may suggest toxic or non toxic nature of goitre; and in lymph nodes it may suggest inflammation or tumor being either primary or secondary in nature. In another example,

swelling in right hypochondrium suggests likely problem in liver or gall bladder anatomically, presence of pain and tenderness suggest inflammation pathologically, and presence of surgical jaundice clinically, makes the most likely diagnosis of inflamed gall bladder [anatomically & pathologically] and obstructed CBD leading to jaundice [clinically]. ‘CBD stone with empyema of gall bladder’ seems to be the obvious first diagnosis.

Principle No. 8 Classify problem

Most of the problems in surgery can be classified in following groups.

1. Congenital.

Either one is born with them, or being dormant they may manifest later in childhood. Ask one question, ‘Since when?’ The answer will either confirm or rule out congenital lesions.

2. Traumatic.

Answer to one question, ‘Did you hurt yourself?’ will often confirm or rule out traumatic lesions.

3. Inflammatory.

There are typical symptoms and signs of inflammation. Pain, fever and tachycardia on general examination; swelling, tenderness, warmth, redness [skin color dependent] and compromised function of the part on local examination; can confirm acute inflammatory lesions. Acute inflammations end by resolution, supuration or death [necrosis, phlegmon, sequestrum, etc.].

Chronic inflammations lead to chronic ulcers, or fibrosis [scars, strictures, contractures, etc.]. Inflammatory lesions may regress in size, unlike neoplasms.

4. Neoplastic.

History of painless progressively increasing lesions, in the absence of trauma or signs of inflammation, is highly suggestive of neoplasm; benign if slow growing and malignant if fast growing.

Neoplastic lesions do not regress in size except in rare situations like central necrosis in large and fast growing tumors.

5. Miscellaneous.

Mechanical [twists, torsions, intussusceptions, volvulus, etc.], metabolic [stones, calculi, etc.], vascular [aneurysms] and many other nonspecific conditions fall in this group.

Principle No. 9. Plan the management

Once the diagnosis is confirmed, management includes treatment and monitoring the progress of the treatment. Treatment can have these three options:

- Conservative medical treatment.
- Guided invasive procedures.
- Surgical explorations; either endoscopic or open.

Treatment may have three results:

- Improvement. [Continue with the treatment].
- Deterioration. [Revise the treatment and look for alternative management].
- No change. [Revise the investigations, diagnosis and management].

Principle No. 10 This is not the end

Make follow up plans, give preventive instructions, and organize rehabilitation strategies.

Non Specific Surgical Conditions

The Pain

As a student I remember reading the following quotation.

“We are born in mother’s pain; we perish in our own”.

How true this statement is!

Pain is the first basic emotion ever felt by a living being.

I describe it as the ‘Cry of tissues for oxygen’.

Anoxia is the root cause of all pain. Hunger for oxygen makes tissues release pain producing substances [PPS], chemicals which irritate the pain receptors at the nerve endings, send afferent impulses which are interpreted by brain as pain.

Pain is defensive mechanism of the body. Brain immediately sends efferent impulses to either to withdraw from the pain causing irritants or to take measures to soothe the pain sites.

There is, however, another kind of pain whose etiology is yet unknown, and which does not require afferent impulses. Painful Phantom limb is the typical example, where there is no limb in which pain is felt; hence there is no question of any afferent impulses. This type of pain originates in brain and is termed as central or projection type of pain. Proctalgia Fugax and Trigeminal Neuralgia are other examples; however there are triggering factors for these pains.

Pain producing irritants are of various natures. They include: mechanical [cuts, pricks and bites], chemical [caustics and poisons], thermal [burns, scalds, and freezing], electrical and radiations, biological [septic inflammations].

Common causes of pain are trauma, inflammations, obstructions and ischaemia. Pain can be somatic, mediated through somatic nerves; or visceral in origin, mediated through autonomic nerves.

Most common cause of somatic pain is ischemia leading to tissue anoxia. Burning pain in skin of most distant structures like toes, and cramping pain [intermittent claudication] in skeletal muscle masses are typical examples.

Other cause of somatic pain is tension in the tissues. Example is oedema due to inflammatory response of the body to any injury, hurt, insult or invasions. Extreme tension in closed spaces leads to Throbbing pain. Typical examples are common headache, earache and hand abscesses.

Visceral pain can be due to extreme contractions of smooth muscles in hollow tubes, severe stretching of capsule of solid organs, erosions of mucous membranes exposing nerve endings and tension in tissues due to inflammatory oedema. Angina is a typical example of constricting visceral pain due to ischemia.

Character of pain varies in different situations and, coupled with the site of pain, can help in leading to the diagnosis.

Colicky pain can be described as Sudden, Sharp, Severe, and Short. It comes and goes and makes the patient double up in bed. It is due to exaggerated contractions of smooth muscles to overcome most often the distal obstruction in hollow tubes of abdomen. Such pain in central abdomen is called Intestinal colic, in right hypochondrium as Biliary colic, and in loin as Renal or Ureteric colic.

Dull aching pain is due to sudden stretching of the peritoneal capsules when solid organs swell up due to inflammation. Such pain in right hypochondrium is caused by acute hepatitis, in loin by acute nephritis, or in lower abdomen in pelvic inflammatory disease. Remember, slow stretching, as in pregnancy, enlargement of spleen in malaria, and ascites, may cause discomfort but not pain.

Stabbing pain, as name suggests, is like knife being thrust in; and is felt at the back due to stretching of capsule of retro-peritoneal structures. Acute pancreatitis is classical example. It also occurs in dissecting aneurysm of aorta.

Burning pain is due to irritation of inflamed or ulcerated mucous membranes. Stomatitis, reflux oesophagitis, gastritis and peptic ulcers, and cystitis are examples of burning pain.

Severity of pain can be graded on 0-10 scale, and can be useful although it is subjective observation.

Associated symptoms with pain also help in diagnosis. Fever and pain on movement suggest an inflammatory etiology, and pain with vomiting suggests an obstructive etiology. Pain increased by food intake suggests gastritis or ulcers. Pain increased by fatty food intake suggests gallbladder inflammations, since diseased gall bladder cannot contract in response to cholecystokinin, released in duodenum by the fatty foods. Anorexia and nausea are common in most of hepato-biliary, pancreatic and upper gastrointestinal tract (GIT), pathologies.

Abdominal discomfort associated with distension and flatulence, is called 'Dyspepsia'; which can be either gastric, biliary or pancreatic in origin.

Absence of pain is equally important. It suggests neuropathy in ulcers, and early neoplasm in swellings. Tumors most often are painless in the early stages.

They cause pain when associated with overstretching of the capsule of solid organs; or when invasion of surrounding structures occur.

The Wounds

Loss of skin on the body as a result of trauma or injury is called 'Wound'. Partial loss of skin is called 'Abrasions'.

Traumatic wounds are classified mainly in two categories which forms the basis of management. They are:

1. Tidy wound, such as clean incised wounds.
2. Untidy wounds, such as lacerated wounds.

Another classification in four categories is based on the status of contamination of surgical sites. Examples are:

1. Clean wounds, when no viscous is opened.
2. Clean contaminated wounds, when viscous is opened but with minimal spillage of its contents.
3. Contaminated wounds, when spillage is from inflamed viscous.
4. Dirty wounds, which are clearly infected.

Most surgical patients have wounds. Wounds require dressings. Clean wounds can be cleaned, dried, closed and sealed by dressings. Clean contaminated and oozing wounds should not be closed or sealed. They should be allowed to breathe and ventilate through porous dressings; they may require frequent dressings. Dirty wounds require cleaning, de-sloughing and debridement, till they become clean. Wounds contaminated with dirt, dust and soil require tetanus prophylaxis.

Healthy small wounds close by themselves slowly. Epithelium grows at an average rate of 1mm per day; hence large wounds may take a long time to close. They may either be closed by sutures or clips and staples; or may be covered by skin grafts. Healthy wounds are closed by primary suturing; unhealthy wounds are closed by secondary suturing or delayed closure after they are rendered healthy.

Sutures, clips in wounds along stress lines and in vascular areas can be removed between 3-7 days. Those across the lines must be left for 2-3 weeks.

Supportive measures are essential for healing. Metabolic states like diabetes must be controlled, infections must be eradicated, and nutritional status should be restored to normal. Other than that, all wounds must be protected from further trauma and re-infections.

Clean wounds heal by primary intention; that is by regeneration of epithelium and minimum repair by fibrous tissue. They leave minimum scar.

Other wounds heal by secondary intention; plenty of repairs by fibrous tissue occur before they are covered by regenerating epithelial tissue.

Fibrous tissue contracts leaving ugly scars and contractures.

Repair of wounds require healthy granulation tissue which is composed of newly forming capillaries and proliferating fibroblasts. It is therefore red, uniform and velvety in appearance and bleeds on touch.

Tissues rich in vascular supply heal better and faster. Infection, ischemia, tension and foreign bodies, which include pus and necrotic dead tissue, are the worst enemies of healing. Similarly wounds in diabetics, immuno-compromised and nutritionally deficient patients take a long time to heal. Certain drugs like steroids and chemotherapeutic agents have similar delaying effect.

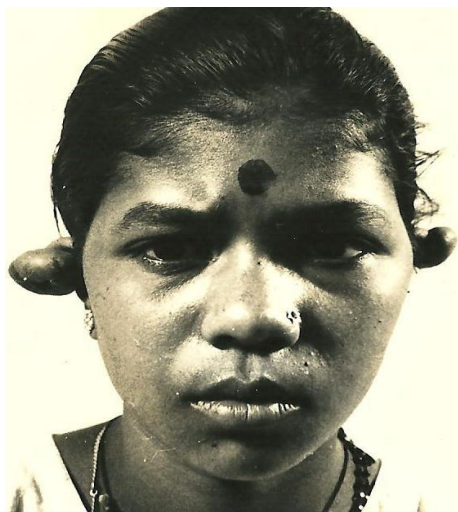Wounds along stress lines in body [Langer's lines] heal faster with minimum scar. Those across these lines take longer time to heal and leave ugly scars.

Wounds start gaining strength from third day onwards. They are strong enough to withstand normal stress within two weeks. However, remodeling and further gaining of strength continues for up to six months.

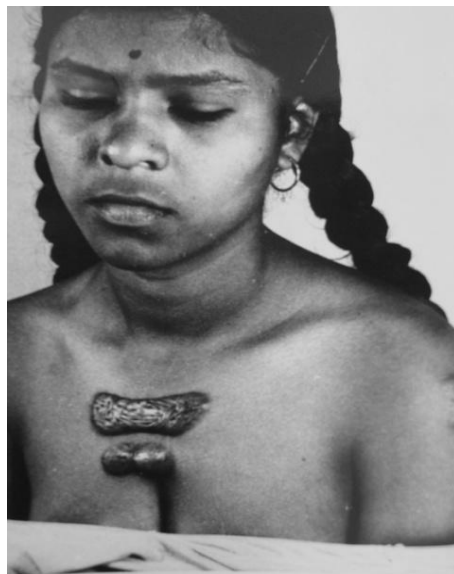Scars

All wounds, when they heal, leave scars. Scar is fibrous tissue, covered by epithelium. All scars are deficient, devoid of nerves and vessels. Most of them are symptomless and fade away with time. In some cases scar may become hypertrophied and give an unpleasant cosmetic appearance; however this hypertrophy remains confined to the scar. Such scars may need revision. Keloid, on the other hand is a complication of scar. Even a small scar of ear piercing can lead to outgrowing keloids. These keloids mainly grow outwards, are only disfiguring, and have minimal symptoms.

Other type of keloids grows inwards and extends beyond the scar, deep into the tissues and has symptoms like severe itching and burning pain. It has racial and genetic tendencies. Recurrence, even after extensive excision is common. [See figures below]



Outgrowing Keloids



Ingrowing Keloids

Haemorrhages

Haemorrhage can be internal or external; and are of three types.

Primary haemorrhage occurs due to trauma or during operations, and must be stopped. Reactionary hemorrhage is the term used for early hemorrhage in post trauma/operative period when collapsed small vessels open up following resuscitation, and start to bleed. Secondary hemorrhage occurs in infected wounds when blood vessels are eroded by inflammatory process. Similar measures will work in both these situations.

As first aid, in hemorrhages of extremities, elevation of the limb above the level of heart, direct compression on the bleeding area can be effective. Temporary proximal compression by bands or tourniquet can also be used; however it must be released intermittently so as not to cause distal ischaemia. Finally the bleeding points may have to be ligated or sutured.

Spontaneous bleeding in skin and mucous membranes is called Ecchymosis. Bleeding and extravasations of blood in tissues due to injury or trauma is called Bruise or Contusion. In these conditions, blood is diffusely spread and cannot be drained.

Collection of blood in tissues is called Haematoma. Aspiration or drainage of blood collection is possible as long as blood remains fluid. Eventually blood clots and cannot be drained; it may need evacuation of clots.

Surgical Infections

Infections are the commonest pathology dealt by surgeons. In addition to primary infective conditions, these include surgical site infections [SSI], nosocomial infections, and cross infections.

Staphylococci, streptococci, E. Coli, proteus, pseudomonas and anaerobes are the usual organisms in surgical infections. Staphylococci produce localized necrotizing inflammations and may end in collection of thick pus, due to their coagulase positive nature. Abscesses, boils, carbuncles, are examples of such lesions.

Boil or furuncle is an infected hair follicle and is self limiting condition. It may spread and become an abscess, requiring drainage.

Carbuncle is infection of many hair follicles in a group at one place, and occurs usually on nape of neck or on back. It is common in diabetics. Wide excision and drainage maybe required in addition to control of diabetes and infection.

Streptococci produce spreading lesions due the presence of enzyme hyaluronidase. Examples are erysipalas, cellulitis, fasciitis and myositis.

However, most of the surgical infections have mixed organisms. Blue or green pus indicates pseudomonas infection; foul smelling pus indicates presence of anaerobes.

Cellulitis is spreading inflammation of subcutaneous tissues. Antibiotics are required. Surgery is not necessary unless abscess develops.

Lymphangitis presents as red streaks in white skinned people; difficult to see in dark skin ones.

Thrombophlebitis is inflammation of superficial veins and may follow as complication of venipuncture. Treatment is conservative.

Migrating or fleeting phlebitis is serious sign of deep malignancies like pancreatic cancer. [Trousseau's sign]

Symbiosis between aerobes and anaerobes can result in severe forms of necrotizing inflammations, especially in debilitated patients.

Melanae's gangrene of abdominal wall, Fournier's gangrene of scrotum and perineum, Phagedena of penis and Cancrum oris around the mouth are examples of symbiotic inflammations.

Necrotizing fasciitis is mixed infection in subcutaneous and deeper tissues. Immunodeficiency states are precipitating factors for this condition. It requires wide drainage, debridement of necrotic tissue and antibiotics. Mortality in this condition is very high.

Inflammation of sweat glands is called Hydradenitis. It is common in obese females and in the axilla and the groin where sweat and sogginess is common. A severe variety is called hydranitis suppurativa, which involves many sweat glands, is very difficult to treat and recurrences are very common.

Abscess is localized collection of pus. Usually caused by staphylococcus, mixed organism may be present. Fluctuation can be elicited in superficial abscesses. Deep ones require ultrasound to diagnose.

Pus is digestive product of dead and dying bacteria, blood cells and local tissue. Pus, wherever it is, must be removed, by aspiration or drainage.

All acute abscesses require drainage. Dead tissue must be desloughed, and thick fibrotic edges must be debrided to promote healing in chronic wounds and ulcers.

When the pus collection is in deep tissues covered by dense fascia, such as the palm of the hand and parotid region, early decompression is essential to prevent necrosis. One should not wait for classical signs to appear. Presence of throbbing pain is enough to warrant early intervention.

Timely interventions are essential. Treatment delayed is treatment denied.

All foreign bodies that delay healing must be removed. Pus, dead tissue, slough and sequestrum act like foreign bodies.

Thin watery pus discharge from ulcers and sinuses indicates chronic infections. Thick cheesy pus, in the absence of signs of acute inflammation, indicates tuberculosis, as in Cold Abscesses. Tubercular cold abscesses arising from deep cervical lymph nodes may track under the skin through deep fascia, and present as fluctuating swelling. These are called 'Collar Stud Abscesses'.

Drainage of cold abscess was contraindicated for fear of ending in chronic sinuses. Instead antigravity aspiration was advised. However with good control of tuberculosis by effective new anti-tubercular drugs, drainage and even excision of cold abscesses can be safely performed.

Tumors

These are neoplastic growths that present as swellings or ulcers. In most cases, cause is unknown; although recent research in molecular biology and genetics is trying to unravel this mystery. Tumors are either benign, which are usually capsulated and grow slowly; or malignant, where growth is very fast. Most benign tumors have high potential for malignant change.

Tumors are the result of uncontrolled growth of tissues by cellular hyperplasia, dysplasia and anaplasia. These are either epithelial in origin [Carcinomas], or mesothelial [Sarcomas].

Carcinomas have no capsule; they grow and spread by infiltration in surrounding tissues. Once vessels are infiltrated, lymphatic or blood spread occurs. In the abdomen cancers can spread all over the peritoneal surface by freely falling malignant cells, called trans-coelomic spread.

Sarcomas usually grow by expansion, and spread by blood stream.

Histologically carcinomas may be well differentiated in their cellular structure and glandular pattern; moderately differentiated, or completely undifferentiated when they are called 'Anaplastic'. This last group has the poorest prognosis.

Tumors of endocrine glands may involve more than one gland of Neuro-Endocrine origin. These are called 'Multiple Endocrine Neoplasia' [MEN], and are divided into two main groups; MEN-1 and MEN-2. Complete evaluation of the patient before surgery on endocrine tumors is very important.

Surgical excision is the treatment of choice for Benign Tumors, if they are bulky, unsightly, causing symptoms, changing their growth pattern, or are known to be premalignant. Radical curative surgery is the treatment of choice

for most Malignant Tumors in early stage. Palliative surgery is required to relieve symptoms in advanced tumors which are not curably resectable.

Certain tumors respond to cancer chemotherapy, either completely as in lymphomas; or partly, when tumor size and its stage can be reduced. This is called neo-adjuvant therapy, and is followed by surgical excision. In other instances chemotherapy is used as adjuvant therapy after surgery, to deal with any remaining cancer cells. It can also be the only therapy in advanced tumors.

Certain tumor cells are sensitive to radiations. Radiotherapy is indicated in such radio-sensitive tumors; pre-operative, post-operative, or as the sole treatment. At times both chemotherapy and radiotherapy are combined to enhance the anti tumor effect; it is then called 'Chemo-radiation'.

Cysts

Cysts are abnormal swellings containing air or fluid; clear thin or turbid & thick.

True cysts are lined by epithelium. False cysts, on the other hand, have no epithelial lining. [Pseudo-pancreatic cyst].

True cysts can be classified as follows.

Developmental cysts: Examples are Branchial cyst, Thyroglossal cyst, Duplication cyst, Mesenteric cyst, Polycystic disease of liver, kidneys, pancreas, lungs, etc.

Malformation cysts: Example, Cystic Hygroma.

Sequestration cysts: Sequestration Dermoids.

Germinal cysts: These arise from germinal layers and are common in testes

and ovaries in the form of Dermoids and Teratomas.

Retention cysts: When ducts of small glands are blocked, secretions are retained forming a cystic swelling. Examples are epidermal cysts and ranula.

Distention cysts: When secretions in the acini of a ductless gland accumulate, they distend the acini forming cysts. Example is colloid cyst of thyroid gland. Pulmonary cysts are also due to distension of alveoli with air.

Degeneration cysts: Solid masses may undergo ischaemic necrosis and degeneration in their center leading to cyst formation. Example is chocolate cysts of ovary.

Implantation cysts: A penetrating foreign body may implant a tiny piece of dermis in subcutaneous tissue causing sub-minimal aseptic inflammatory reaction and cyst formation called implantation dermoid cyst.

Parasitic cysts: Classical example is hydatid cyst. Parasite causes lesions where germinal layer secretes fluid leading to formation of cyst and floating daughter cysts which look like grapes.

Common Lesions of Skin and Subcutaneous Tissue

Simple Benign Lesions

Epidermal cysts, earlier called sebaceous cysts, are the commonest. They arise from sebaceous glands and occur in hairy areas such as scalp, scrotum, chest, etc. They are attached to the skin as a black spot from where the hair fell. They contain thick cheesy sebum. Complications include infection, ulceration, and rarely the sebaceous horn. Small ones can be left alone. Large, unsightly or infected ones require excision. Recurrence is common.

Dermoid cysts are subcutaneous and overlying skin is free. They contain embryological derivatives of at least two germinal layers; such as hair [epidermal] and teeth [mesodermal]. They are usually symptomless and removal is required for cosmetic reasons only.

Congenital variety is called sequestration dermoid, and is found at the embryological points of fusion such as midline of scalp and external orbital angle.

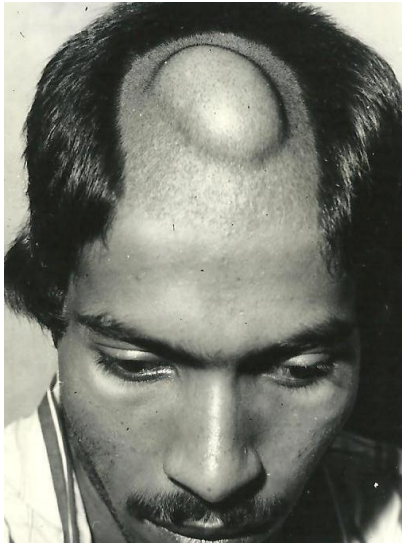
Acquired variety is called implantation dermoid, and is common in barbers in webs of fingers. It can occur at other puncture sites also.

Warts and Papillomas are benign tumors, usually caused by viruses. They are multiple, vary in size and shape and require removal for cosmetic reason only.

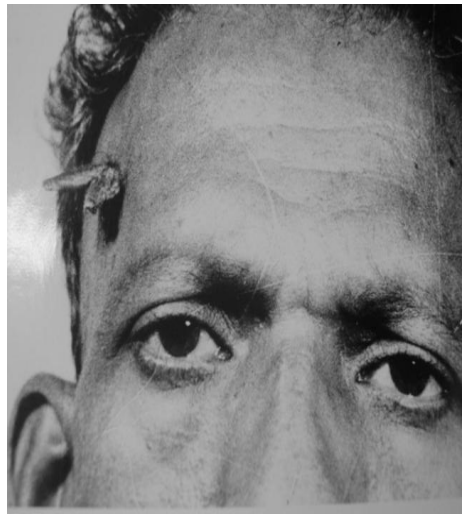
Callosities are hypertrophy and thickening of superficial layers of epidermis on friction points. These are avascular, painless and do not require any treatment.

Corns are similar but have a wedge shaped extension into dermis; hence they are vascular and very painful on pressure. Application of corn caps or salicylic acid ointments can soften the surface and relieve the pain. Avoiding pressure by padding the shoes on pressure points is also helpful.


Neurofibromas on the other hand are painful. Multiple neuro-fibromatosis [Von Recklinghausen's disease] has a genetic basis. Plexiform neurofibromas can be of very large size, specially on the scalp and face.



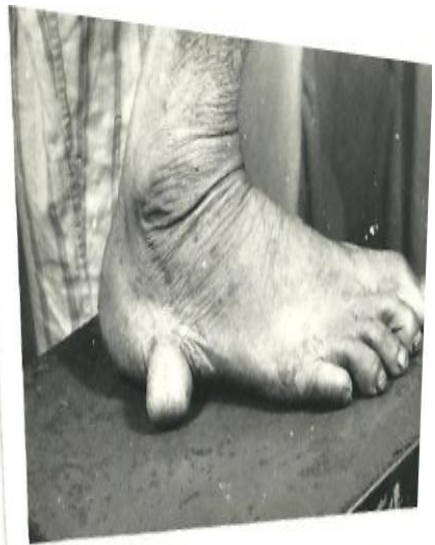
Sebaceous cyst of scalp



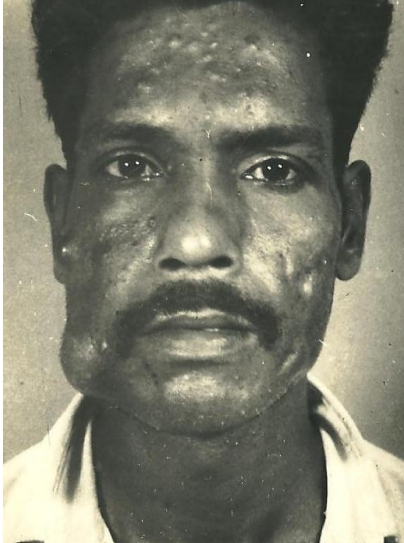
Sebaceous horn



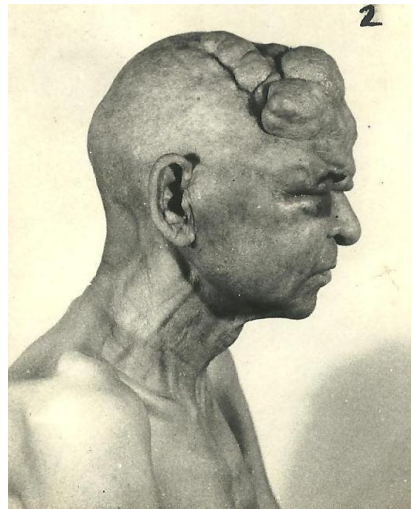
Sequestration dermoid of scalp



Implantation dermoid of foot



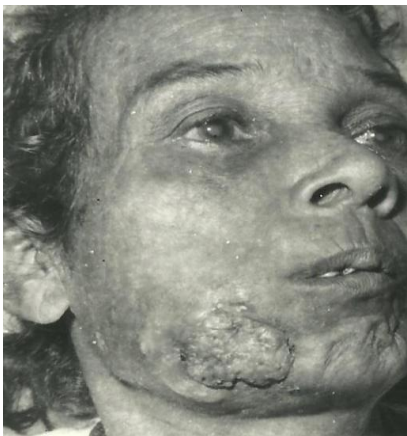Multiple neurofibromas



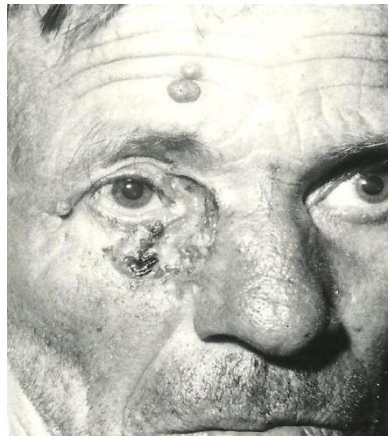
Plexiform neurofibroma

Neoplastinc Lesions

Malignant tumors of skin are squamous cell cancers and basal cell cancers. Cancer arising in a chronic non-healing ulcer is called Marjolin's ulcer.



Squamous cell carcinoma



Basal cell carcinoma

Moles/Naevi

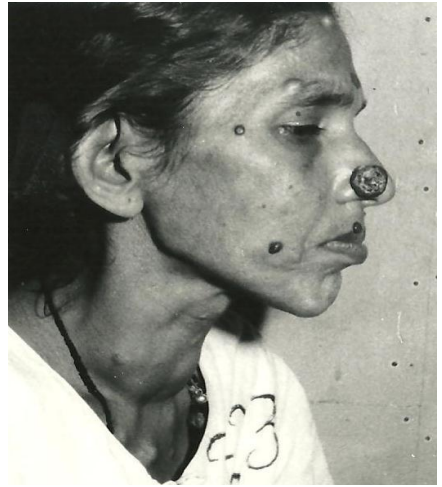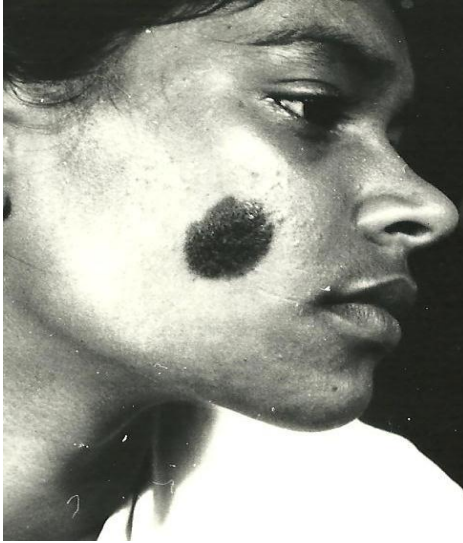Mole is a collection of melanocytes in layers of epidermis, as a result of embryological migration from neural crest. Nevus is a similar collection in dermis. Both are simple, benign and have no malignant potential. However, if a lesion shows change in its behavior such as sudden increase in size, itching, ulceration or bleeding, malignant change should strongly be suspected and an excision biopsy of the lesion is essential.

Malignant melanoma is a serious tumor and can occur wherever melanocytes are present such as skin, retina and bowel mucosa. Skin is the commonest site for melanomas and ultraviolet radiation is a strong risk factor. People with dark skin are more prone to develop malignant melanomas. The spread of the tumor is mainly by lymphatics to regional lymph nodes, and by blood stream to liver and lungs. Even a small lesion like a black spot under the toenail can be a melanoma [sub-ungual melanoma] and may present with distant metastases in inguinal nodes or liver.

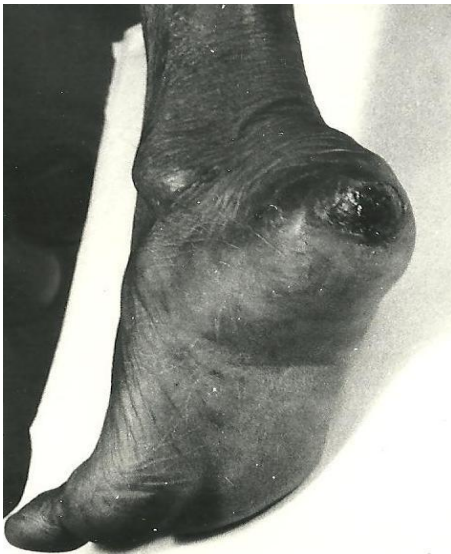Wide excision of the local lesion and radical block dissection of regional lymph nodes provides the best chance for cure.

Congenital birth marks include strawberry naevus, port wine stain. Acquired ones are spider naevi and Campel de Morgan spots, both associated with severe liver disease.

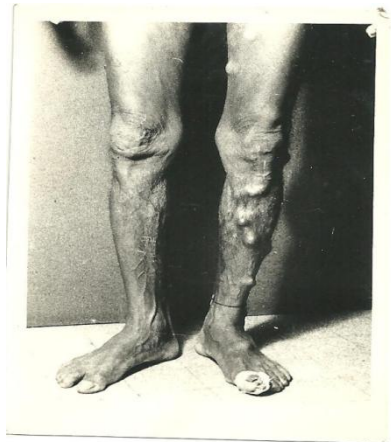Haemangiomas are localized, vascular pigmented lesions. They are usually present at birth and typically show the sign of compressibility. Small ones may regress with time; others may require surgical excision. Large haemangiomas may respond to systemic treatment by steroids.



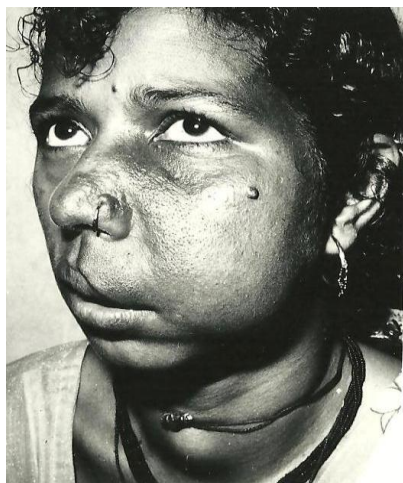Pigmented Naevi of face



Melanoma of heel



Melanoma of big toe with lymphatic metastases

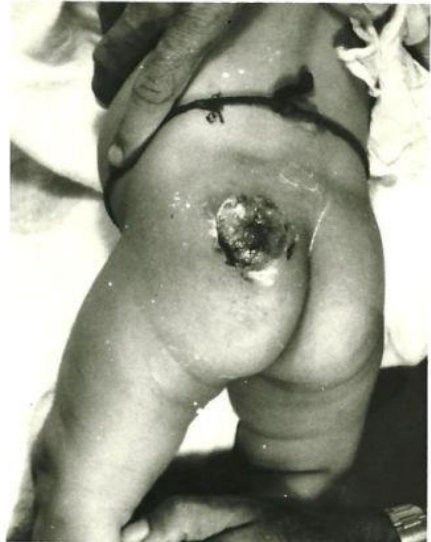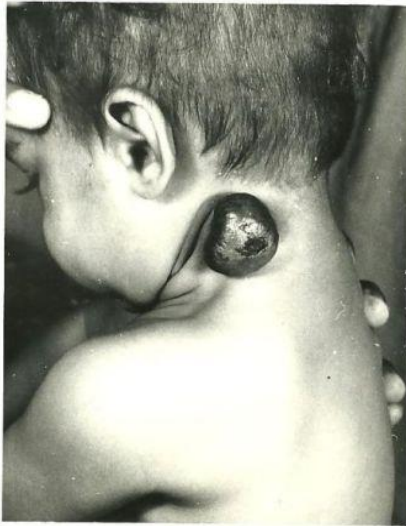


Haemangiomas of face

Vascular malformations are highly vascular lesions. High flow lesions may reveal a thrill and bruit on examination. These lesions grow with age and cause hypertrophy of the region, even gigantism, unlike haemangiomas. Consumptive coagulopathy can be a serious complication. Management option includes identifying the feeding vessel and embolizing or ligating it. Attempt at surgical excision can be quite challenging and may lead to very severe haemorrhage when many feeding vessels are involved.

Glomus tumors are subcutaneous arterio-venous shunts that occur on skin or under the nail bed and can be very painful. Excision is advised.

Kaposi sarcoma is a variety of angio-sarcoma, associated with immunodeficiency syndromes and viral infections such as HIV and herpes virus.



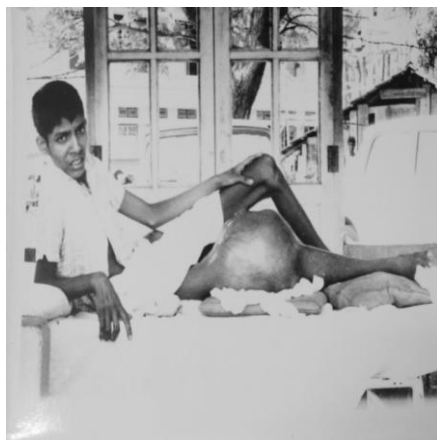Vascular malformations of neck and gluteal region in children

Benign tumors of subcutaneous tissues are lipomas & Fibromas. They usually are small, may be multiple and are symptomless. Malignant change is rare. Excision is advised for large tumors and for cosmetic reasons only.

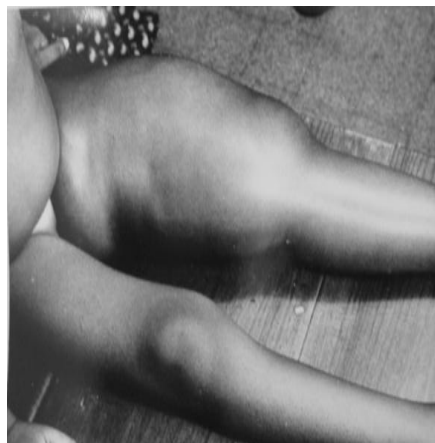Malignant tumors of subcutaneous tissue are Sarcomas. Usually they occur at an early age and present as painless progressive swelling in the limb. They grow by expansion and spread mainly by blood stream. Fortunately they are rare.

Fibro-sarcomas and lipo-sarcomas arise from subcutaneous tissue.

Osteo-sarcomas present in the same way and arise from long bones of the limb.



*Osteo-sarcoma of thigh in a
14 year old boy*



*Fibro-Sarcoma of thigh in a
4 year old girl*

Peri-Operative Care

An operation is merely a part of the holistic management of a patient. Success of operation depends on at least three factors.

First factor is the art and technique of operation; appropriate choice of the procedure, and its execution with minimum collateral damage to the healthy tissues. A technically successful operation is meaningless for the patients if the final outcome is not as per their expectations. This also emphasizes the importance of informed consent and continued meaningful dialogue between patient and the managing team.

Second factor is related to the patient in the form of pre-operative assessment and preparation for surgery, in order to achieve the most satisfactory outcome.

Third factor is environment related; and includes sterility standards of the theater suit, antiseptic precautions, availability of appropriate instruments, optimally working equipment without any possible hazards, and trained support staff.

Peri-operative care includes pre-operative preparation, intra-operative care and post-operative complications and their management.

Preoperative Preparation

This starts with obtaining 'Informed consent' of the patient/relatives and by evaluating the risk status of the patient using one of the many scoring systems. System generated by the American Society of Anesthesiologists [ASA scoring system] is the one most commonly used. It calculates potential risk factors. High operative risk includes extremes of age, undesirable habits like smoking, coexisting medical conditions, medications if any, and current haemo-dynamic and cardio-respiratory status. An elective surgical procedure is postponed till near normal physiological state is achieved. Prophylactic heparin is given to patients at high risk for DVT. Special preparations may be required before surgery, depending on the procedure, such as bowel preparation, exchange transfusion, haemodialysis, etc.

In emergency surgery, high risk consent is taken and critical care monitoring is initiated.

Intra-Operative Care

This includes guaranteeing a near normal physiological status of the patient while asleep, as well as after coming out of the effects of anaesthesia. It is important to keep a constant surveillance on monitoring screens, checking vital signs; pulse, respiration, blood pressures and body temperature. Digital oxymetry for oxygen saturation and checking hourly urine output to regulate IV fluids are equally important.

Alert monitoring avoids situations such as hypoxia, dehydration, and temperature fluctuations. Everyone should remain prepared for any sudden

unwanted developments.

Postoperative care recognizes developing complications, if any, in time and takes steps to deal with them.

In many situations surgeon has to use drains. Their function is to remove undesirable collections. Once drainage stops, drains can be removed.

Postoperative Complications and Management

In immediate postoperative period [first 24 hrs] bleeding from operative site and pulmonary complications are likely events. Main causes for the 'Post-operative pulmonary complications' are pre-existing pulmonary conditions, intubation trauma, effect of anesthetic gases, and inability to sit, move or cough due to pain. This leads to excessive trachea-bronchial secretions and their retention leading to atelectasis, bronchitis, and aspiration pneumonias. Early mobilization of patient and chest physiotherapy, are preventive measures.

During first postoperative week, infections, at surgical site, chest or urinary tract if catheter has been used, are likely. Wound dehiscence, partial or complete can occur, requiring supportive or surgical approach. It can be suspected by thin serous discharge from fresh post-operative wounds. Few common causes include poor nutrition, poor closure and excessive intra-abdominal pressure.

By the end of first week, deep vein thrombosis [DVT] can manifest by pain in the calf muscles, tenderness on squeezing, oedema of leg and unexplained fever. Pain in calf on dorsiflexion of the foot on same side [Homan's sign] may be present. However both these maneuvers can be dangerous procedures since a fragment of newly formed thrombus may detach and lead to pulmonary embolism. Duplex sonography can confirm the diagnosis, and is replacing venograms. Elevation of leg can reduce oedema. Anticoagulation, coupled with

pressure stockings on legs while ambulating is required.

Late complications include decubitus ulcers, incisional hernias, etc.

Critically ill and high risk patients require ‘Critical care monitoring’ in surgical ICU. Oxygenation, perfusion, fluid and electrolyte balance, nutritional status and drug levels in blood are monitored. Swan-Ganz catheter, trans-oesophageal Doppler probes, and thermal sensors may be useful in such cases.

Meaningful communication with the patient and the family before surgery as well as after surgery can minimize the natural psychological anxiety and distress.

It is a philosophical truth that an understanding and cooperative patient and the family, can enhance favorable outcome and minimize the risks of complications.

Swellings and Ulcers

I found teaching swellings and ulcers, the easiest; everyday examples help a lot in explaining this to the students.

First step is to make the Anatomical diagnosis. Answer to one question, ‘Where is the lesion?’ suggests that it has to be related to anatomical structures in that area.

Next is the Etio-pathological diagnosis. Answer to ‘Why the lesion?’ suggest the probable cause. By this question traumatic swellings or ulcers can be confirmed or excluded. In most cases history and physical examination findings can help in suggesting Pathological diagnosis; such as congenital swellings [since when]; inflammatory [symptoms and signs of inflammation], vascular

[compressible or pulsatile], hernias [cough impulse and reducibility], or neoplasms [painless progressive growth].

In certain situations special tests help in diagnosis such as movement of swelling on swallowing or on protrusion of tongue.

Clinical diagnosis is to establish the stage and extent of the lesion, and the effects of the lesion distally [vascular or neurological effects], proximally [lymph node involvement, or systemically involvement of other systems by metastasis]. All the above put together, help to make a list of probable conditions causing the lesion [Differential diagnosis]. Relevant investigations can then clinch the final diagnosis. Other than the site, clinical features of swelling or ulcer on physical examination are very helpful in diagnosis. To teach these I use simple things in common use in our day to day life.

Swellings

For swellings I place on the table the following: an apple, a pear, a banana, an orange, a pine apple, a sponge, a cup of ice cream, a small balloon filled with water and another filled with juice. Then we inspect and describe the swelling.

Shape is round as in apple, oblong as in pear, long as in banana. Color also may indicate the difference between swellings; such as red in inflammations, black as in melanomas, blue as in haematomas and so on.

Margins of all in this example are well defined unless I cover them with a cloth; then they become diffuse. Other observations include, any pigmented spots or marks as on spotted banana or scratched apple; or abnormal movements like pulsations; [not in fruits].

Then I cover them all by a piece of cloth and ask them to feel i.e. Palpate.

Shape and margins are confirmed. Surface can be smooth in apple and banana, granular as in orange, nodular as in pineapple. Gentle pressure causing pain is Tenderness in body swellings.

Then I ask them to press a little more and feel. Apple feels 'Hard'; orange feels 'Firm'; Ice cream cup feels 'Soft'; Balloons feel 'Soft and Cystic'. This is called 'Consistency' of swelling. It describes the nature of swelling's contents. Although both the cup of ice cream and the balloon are soft, one contains solid cream while the other contains fluid. The test to differentiate these is called 'Fluctuation'. Fluctuation cannot be elicited in reducible swellings. To elicit fluctuation first hold the balloon so that it does not move. By pressing on one side of the balloon, the water inside can be moved and the wave can be felt by the finger placed on the opposite side. This can be repeated on the other two opposite sides. When the wave is felt on both sides, the fluctuation is positive meaning contents are 'Fluid'. Negative fluctuation however does not exclude fluid in the swelling; these are exceptions. Tender Coconut has water in it, but no fluctuation because walls are very thick. A football has air but fluctuation cannot be elicited because the air is under tension. Please note that if consistency is hard or firm, eliciting fluctuation is superfluous. It is relevant for soft swellings only. Since fluctuation is positive in both balloons indicating presence of fluid, its nature now has to be established. I ask them to pass beam of light from one side and see on the other side, through a rolled up paper to make it relatively dark and so easy to see. Balloon with water is described as 'Translucent'; meaning contents are 'Clear fluid'. Light does not pass through other balloon containing juice, meaning contents are turbid or thick and the test is negative.

Mobility means all items can be moved on the table, unless they are nailed to it; when it is called 'Fixed swelling'.

When a sponge is pressed, it changes in shape and size, but regains the same when pressure is released. Such swellings are described as 'Compressible'. Examples are vascular swellings.

Swellings connected with cavities may disappear on pressing and reappear on straining; they are called 'Reducible'. Examples are external hernias.

Swelling is called 'Pulsatile' when examining fingers feel pulsations over the swelling. If two fingers placed apart on the swelling move straight up and down, it is called 'Transmitted pulsation, meaning swelling is overlying some major artery. If fingers move apart, away from each other, it is called 'Expansile pulsation', meaning that the swelling itself is of a major artery as in aneurysm.

With all the information derived from the above described tests, one can get a reasonable idea about the nature of the swelling and its contents.

Swellings in special situations like abdomen can be Percussed to see if they are dull like solid organs or resonant like bowel. Auscultation by stethoscope is used for the presence of any bruit as in vascular swellings and for exaggeration or absence of bowel sounds.

In limbs, area distal to the swelling is examined for any effects, and area proximally for lymph nodes enlargement.

If swelling itself is suspected to be lymph nodes, all area drained by that group of nodes must be examined, along with all other lymph nodes in the body and the liver and spleen in abdomen.

Ulcers

Ulcers are breach in continuity of skin or mucous membranes. When wounds persist, they are termed 'Ulcers'.

To teach ulcers, I place a small cup on the table, denoting an ulcer, with a few drops of juice in it. The site is noted and the size is measured in two directions, maximum and minimum measurements of the margin. Margins of the cup are regular; in some ulcers they may be irregular, as in lacerations.

Peeping into the cup, shows the Floor which in this case, is covered by juice. Floor of ulcers may be covered by granulation tissue, pus or wet necrotic tissue called 'Slough'.

Inner wall of the cup is 'Edge', which joins margin to the floor. When size of the outer margin of ulcer is larger than the floor, edges are described as 'Sloping'. It means ulcer cavity is filling up from below as happens in healing ulcers. When opening and floor are of same size, Edge is called 'Punched out', as in neuropathic [trophic], and chronic ulcers.

When size of floor is bigger than the opening, edge is called 'Undermined'. It denotes that destruction is going on below under the skin flaps. This edge is typical in tubercular ulcers.

At times the raw area is not deep but Elevated above the margins, either straight [Rolled up edge], or overflowing edge like a cauliflower. It denotes that cell proliferation is excessive and uncontrolled. This is highly suggestive of malignancy; although same may occur in lesions such as septic granulomas.

Table on which cup is placed is called 'Base'. Ulcer [cup] may be moved on the floor or may be fixed to it, as in ulcers over the bones and joints.

Attention is now focused on the area surrounding the ulcer for signs of inflammation or of ischaemia. In limbs, major blood vessels are palpated and neurological examination is completed. Lastly all lymph nodes proximal to the ulcer are palpated. They are usually enlarged in infective and neoplastic ulcers.

Information derived from all the above examinations helps in making a probable diagnosis of the cause of ulcer. Investigations including examination of discharge, imaging of the area and, even biopsy from edge, may be required to make a final diagnosis.

Etiologically ulcers can be classified as Specific ulcers [Tubercular, vascular, neuropathic trophic ulcers, etc.], and Nonspecific ulcers where cause is unclear.

Pathologically ulcers can be classified as Healing ulcer and Non healing ulcers.

Healing ulcers have sloping edges and healthy pink velvety granulation tissue which bleeds on touch since it is composed of newly forming delicate blood vessels. There is minimal sero-sanguinous non smelling discharge. Surrounding area is warm, pink and non tender. Such small ulcers will heal in time; larger ones are ready for some form of skin grafting.

Non-healing ulcers have margins other than sloping, floor is covered with slough, pus or unhealthy tissue, discharge is dirty and smelling and surrounding area shows evidence of septic inflammation.

Causes for non healing of ulcers are, continued irritation, inflammation and infections, pus and necrotic tissues, foreign bodies, nutritional deficiencies such as anaemia, hypo-proteinaemia, deficiencies of vitamins and trace elements, immuno-compromised status and diseases like diabetes, external agents like steroids and chemotherapeutic drugs.

Objective of treatment of ulcers is to convert unhealthy ulcers into healthy ones so that they can heal by themselves or may require closing or covering by skin grafts.

Malignant ulcers require wide radical excision.

Diseases and conditions responsible for specific ulcers must be treated simultaneously.

Newer techniques to promote healing include de-sloughing dressings, vacuum dressings and use of sonic vibrations to enhance vascularity of the area.

Sinuses and Fistulae

Sinus is described as a rolled up ulcer. Unlike ulcer it has small opening and long deep edges ending in closed end. Its floor cannot be seen and walls [edges] are lined with granulation tissue. A sinus is an evidence of non-healing situation. Causes include persistent infection [tuberculosis], foreign bodies, [hair, stitch or sequestrum], or if the walls become epithelized. Common disease presenting with sinuses are tuberculosis, diabetes, chronic osteomyelitis, pilonidal sinus, buried stitch as after operations [stitch sinus].

Fistula is a tube, like sinus, but it connects two epithelial surfaces, between skin and inner tubes, or between two or more inner tubes. The name depends on the connected organ or the type of efflux. Accordingly external ones are gastric, duodenal, intestinal, biliary, urinary and faecal fistulae. Internal fistulae occur between tubes in the body. Examples are traco-oesophageal, gastro-colic, and colo-vesical fistulae.

Trauma

Trauma is the major cause of death in the young. Time is the most important factor. Time to assess, and time to respond greatly influence the outcome. Quickly perform the primary survey and start resuscitation where necessary.

Primary survey and resuscitation protocol includes:

- A. Maintain Airway, protecting cervical spine.
- B. Assure normal Breathing and ventilation.
- C. Maintain Circulation. Control external haemorrhage.
- D. Disability. Perform neurological [Glasgow coma scale] and musculoskeletal survey.
- E. Expose, perform secondary survey from head to toe, and evaluate for any other injuries.
- F. Follow up. Re-evaluate, and Revise, if necessary.

Triage and assess the severity of injuries, especially in multiple or mass casualties.

- A. Injuries which are instantly fatal, or likely to be fatal in spite of assistance.
- B. Injuries which may not be fatal, if timely intervention is provided.
- C. Injuries which are not likely to be fatal, even if intervention is delayed.

It is the second group which must receive priority attention to save life.

Trauma may be due to a variety of agents. These include Mechanical, Thermal, Chemical, Electrical and radiations, and explosions and blasts.

Causes of Mechanical trauma are road traffic accidents, falls from heights, direct injuries, blunt or penetrating, and crush injuries.

Thermal trauma is due to extreme heat or cold. Burns scalds and freezing injuries fall in this group.

Electrical injuries have local burns as well as rhythm disturbances of the heart.

Explosions and blasts cause a variety of injuries, direct with flying shrapnel, and compressing effects of the widening pressure wave. In high intensity blasts and explosions people in the near vicinity may be compressed to death without any direct injury. This can happen even with under water explosions.

Similarly High velocity missile injuries too have local effects at the points of entry and exit; as well as damage to all the tissues in the path of the bullet. Such missile tracks have not only a charring effect due the heat generated by the missile but also the potential risk of infections due to contamination by the atmospheric air which is drawn in by the suction effect of the high velocity missile.

Burns and Scalds

Thermal trauma results in superficial or deep burns. Superficial ones heal by regeneration of epithelium; deep ones result in scarring and contractures. Excessive scarring may lead to hypertrophic scars and keloids. Danger to life from burns is due to loss of fluid and proteins; and to secondary infections. Immediate treatment requires adequate fluid replacement, in quality as well as quantity. Loss depends on the percentage of body surface area involved in burns. Calculations for fluid requirements take this into account. Many formulae are available for these calculations in different age groups.

Circumferential burns in limbs cause compartment syndrome due to inflammatory oedema under thick unyielding eschar. Distal gangrenes can occur due to compromise of vascularity. Timely escharectomy can save the limbs. Large raw areas may require repeated skin grafts to expedite healing. Aseptic and antiseptic techniques are essential to prevent infections and to promote healing.

Inhalation burns caused by fire and hot smoke, damage the respiratory

mucous membranes, may cause laryngeal oedema, and respiratory obstructions. In severe cases tracheostomy may be required.

Severe External Haemorrhage

Diagnosis is obvious.

To stop bleeding in limbs, use elevation of limbs, apply direct pressure, or indirect proximal pressure by any means, cloth, bands, tourniquet, keeping in mind the time factor, and if signs of distal ischaemia appear, release pressure intermittently.

Mangled extremities require immobilization of limbs and team approach.

Management of trauma cases is a team effort and should follow the ATLS protocol.

It basically includes maintaining the airway and normal breathing, resuscitation and control of external bleeding, covering the wounds and support to damaged parts.

Management of trauma in abdomen and chest is discussed in respective chapters.

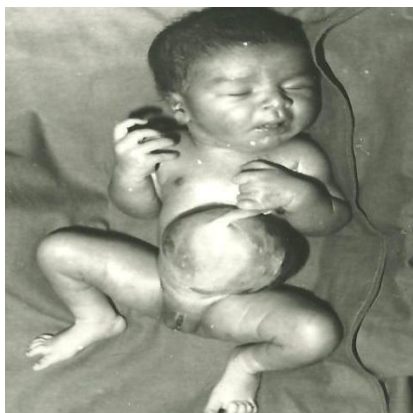The Abdomen

Developmental Defects of Abdominal Wall

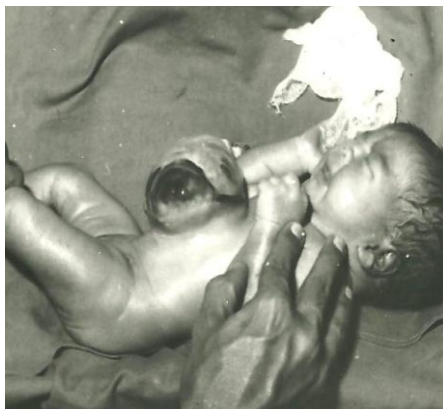During embryonic stage, most of the abdominal viscera develops in coelomic cavity, most of which lies outside the abdomen. However it returns to the abdominal cavity before birth and requires rotations to accommodate itself in the confines of the limited abdominal space.

In some instances it fails to return before birth and baby is born with abdominal viscera remaining outside in a peritoneal sac. The condition is called 'Omphalocele'. Surgical approach is required to return the viscera and repair the defect. It may have to be done in stages.

In extreme cases, even the peritoneal covering is missing. This condition is called 'Gastroschisis'. Surgical approach includes immediate covering of viscera with mesh and slow manipulative reduction. Mortality is very high in these cases.



Omphalocele



Gastroschisis

Surgical Abdomen

Two conditions in the abdomen are of special importance for surgeons. They are; Acute abdomen, and Abdominal masses. Approach to these two conditions will be discussed in detail in this chapter.

Acute Abdomen

Acute pain in abdomen, of sudden onset, is called acute abdomen. Common causes are:

- Inflammations
- Perforations
- Haemorrhages
- Obstructions
- Ischaemia

Inflammations

Acute Inflammations of significant surgical interest include:

- Appendicitis
- Cholecystitis
- Pancreatitis
- Diverticulitis
- General peritonitis

Chronic inflammations of surgical interest are chronic cholecystitis, chronic pancreatitis and inflammatory bowel diseases, specially tuberculosis and Crohn's disease.

Main Symptoms

Pain, of various character and intensity, is a constant and important feature of all inflammatory lesions in abdomen. Nausea, Vomiting and Fever are nearly always present, along with acute pain, in all acute inflammatory abdominal conditions.

Dyspepsia is a term used for vague symptom complex which includes anorexia and aversion to food, abdominal discomfort after meals and feeling of fullness even after small meal. Abdominal distension, flatulence, gaseousness,

frequent eructation and passage of gases, nausea and vomiting are invariably associated.

Symptoms of dyspepsia are usually associated with acid peptic gastro-duodenal diseases [Gastric dyspepsia], chronic cholecystitis, cholelithiasis and cholesterolosis [Biliary dyspepsia], chronic pancreatitis [Pancreatic dyspepsia] and a number of intestinal conditions including diverticulosis and parasitic infestations [Intestinal dyspepsia].

Saint's triad describes a group of three conditions which may exist together and which may have similar abdominal symptoms including dyspepsia. These are cholelithiasis, sigmoid diverticulosis and hiatus hernia. All three are common in obese persons.

Physical Signs

Physical signs in most of acute inflammatory conditions of abdomen also are more or less the same and are localized to their anatomical region. In general peritonitis which usually occurs as complication of other acute inflammations in abdomen, physical signs are diffusely present all over the abdomen rather than localized.

In localized acute inflammations, Local Tenderness is according to the site of inflamed organ.

Attempt to press at the site of pain evokes voluntary contraction of muscles. This is called Guarding. It is a defense mechanism, since pressure on, or movement of the inflamed organ increases pain.

If pressure is maintained without any further movement, pain may seem to decrease, since inflamed organ is no longer moving. If at this point the hand is suddenly lifted off, same pain returns making patient to wince. This is called

Rebound tenderness, since while lifting the organ has moved again.

Acutely inflamed appendix can also be moved by pressing on left iliac fossa [LIF] which causes pain in right iliac fossa [RIF]. This is called Rovsing's sign.

If inflammation is very severe, and involves local parietal peritoneum, the covering muscles are involuntarily in spasm, making them rigid. This is called Rigidity.

Signs of guarding and rebound tenderness become irrelevant and have no place when rigidity is present.

Other signs like Psoas sign, suggest Retrocaecal Appendicitis or involvement of psoas muscle. In this case right hip may be in flexed position and attempt to extend will cause pain. Similarly, if flexing and laterally rotating the right hip cause pain in RIF, it suggests Pelvic Appendicitis. This is called Obturator sign.

These signs need to be elicited only if classical signs in the RIF are not present.

In Acute Cholecystitis, gall bladder may be sub hepatic and local signs may be difficult to elicit. Attempts are made to bring down the gallbladder by deep inspiration while maintaining pressure at the tip of ninth costal cartilage in right mid-clavicular line. If gallbladder is inflamed, this maneuver will cause pain and the patient will hold the breath. This is called Murphy's sign, and when positive, suggests Acute Cholecystitis.

Acute Diverticulitis produces similar signs in the left iliac fossa, like tenderness, guarding, rebound tenderness or rigidity.

Pain on coughing in either fossa also suggests inflammatory process in that area.

Acute Appendicitis

Acute appendicitis is diagnosed by typical symptoms of pain, which starts around umbilicus and then shifts to right iliac fossa [Shifting pain], vomiting and fever, in that order; and by typical signs of tenderness and rebound tenderness in RIF. It is supported by leucocytosis.

In children, Meckel's diverticulitis and Mesenteric lymphadenitis closely mimic acute appendicitis. In latter condition, tenderness shifts from one place to another in abdomen [Shifting tenderness], and throat infection is usually present.

In females, urinary infection, pelvic inflammations, ectopic pregnancy and ruptured ovarian follicle [Mittelsmerz pain], can present as acute appendicitis.

Imaging by ultrasound/CT scan is helpful in diagnosis. Diagnostic laparoscopy is the last resort, and can be therapeutic too.

Appendectomy is the correct treatment in early stages of acute appendicitis.

If treatment is delayed, body attempts to isolate the inflamed appendix by wrapping it up with omentum and surrounding it with loops of small intestine. This forms 'Appendicular Mass'. If mass is felt on palpation, Conservative Management is advised. This includes, NPO, IV fluids, broad spectrum antibiotics and analgesics. Surgery is contraindicated for fear of spreading the infection and possibility of damage to bowel during dissection. Mass should be marked on surface of abdomen so that its progress can be followed. Improvement in symptoms and signs, and reduction in size of mass suggest resolution of inflammatory process. Appendectomy is delayed for 6-8 weeks and is performed as an elective procedure.

Mass however, may not resolve in some cases, and proceed to suppuration,

forming an 'Appendicular abscess'. Increasing pain and vomiting and swinging temperature are suggestive of abscess. In doubtful cases, imaging by ultrasound or CT scan can confirm presence of pus. Appendicular abscess requires drainage, by image guided or open technique.

In some cases an appendix which is obstructed by faecolith, may cause obstructive appendicitis and lead to early perforation. This may present as localized abscess or generalized peritonitis. Patients at extremes of age are more vulnerable for early perforation and peritonitis. Management is surgical.

Diagnosis of acute appendicitis may not be so obvious in all cases. Standard investigations and a period of observation may not resolve the issue.

In such cases diagnosis of 'Non Specific Abdominal Pain' [NSAP] can be entertained. Symptoms are short lasting and condition resolves spontaneously. However this diagnosis should be considered only after common acute inflammations have been excluded and condition of the patient remains stable during the period of observation.

Acute Cholecystitis

Cholecystitis is an acute or chronic inflammation of gallbladder. Invariably it is secondary to gall stones. Rarely, Acalcular cholecystitis may occur; in this case, gall stones may form secondary to inflammation.

Risk factors for cholecystitis are Females, Fertile, Fat [obesity], and Forty plus age.

Diagnosis of Acute Cholecystitis is made by Acute Pain in right hypochondrium, nausea, vomiting, fever and positive Murphy's sign.

Pain usually radiates to the back; and is referred to right shoulder if

diaphragm is irritated, due to common roots of innervations, C-4 and C-5, which supply the dermatomes [skin] of shoulder and myotomes [muscles] of diaphragm.

Leucocytosis is invariably present. Ultrasound can confirm presence of inflammation by thickened oedematous wall and presence of stones.

Current treatment of acute cholecystitis in early stages, in the golden period of first twenty four hours, is Laparoscopic cholecystectomy. Open cholecystectomy is rarely performed nowadays.

For cases who present late, conservative management with broad spectrum antibiotics is acceptable. In such cases interval Elective Cholecystectomy after 6-8 weeks is advised.

Chronic Cholecystitis and Cholesterosis of gallbladder [Strawberry gallbladder] present with Biliary Dyspepsia.

In biliary diseases, Fatty meal increases pain in right hypochondrium. This is because fats in duodenum release Cholecystokinin, which makes the gall bladder contract to release bile. Inflamed gallbladder does not like it, hence pain is increased.

Thick walled and poorly functioning gallbladder with stones can be diagnosed by imaging techniques such as ultrasound.

Laparoscopic Cholecystectomy is the treatment of choice.

For the operation of cholecystectomy, especially by laparoscopic technique, knowledge of anatomy of the area, particularly of Calot's triangle is very important to avoid injury to or accidental clipping of main bile ducts.

Slipping of clip or ligature from the cystic artery or duct may lead serious

intra-peritoneal hemorrhage or bile peritonitis in early postoperative period.

Complications of Acute Cholecystitis can be serious.

If cystic duct is blocked by stone or oedema, and if inflammation is mild, Mucocoele of gallbladder can occur. It can convert into an Empyema of gallbladder if the inflammation is severe. This requires emergency decompression of the gallbladder, preferably by image guided drainage.

A large stone in cystic duct or Hartman's pouch can also cause obstructive jaundice by pressing on or ulcerating into the main bile ducts. This is called Mirizzi syndrome.

Severely inflamed gallbladder can rupture and cause local or general peritonitis; or it can form fistula with duodenum. In this situation, stone from gallbladder can slip in duodenum, pass downwards and increase in size while moving. Finally it may block ileocaecal junction, causing what is termed as Gall Stone Ileus, a form of intra luminal intestinal obstruction.

Gallstones

Gallstones can form in gallbladder or in bile ducts.

Gall bladder concentrates bile by absorbing water, and it secretes mucous from its goblet cells when inflamed or irritated. By this process bile becomes supersaturated and solutes in bile such as bile pigments and cholesterol get precipitated. These crystals get bound together by colloid mucous and a stone is formed. If bacteria are present, they may form the nidus for the stone.

Gall stones may be composed of pure cholesterol. These stones are usually solitary, large, white, and with radiating cut surface. Other types of gallstones are composed of pigments. They are small, multiple and usually colored black

or brown. Black stones occur in gallbladder while brown stones are formed in main bile ducts due to stasis. Presence of infection creates mixed stones which develop in multiple crops of varying sizes. They are dark in color, and have concentric cut surface.

Gallstones may lead to Biliary colic. This is due to exaggerated contractions of gallbladder to overcome any obstruction to outflow of bile in main bile ducts.

Obstruction in cystic duct may cause Mucocele or Empyema of gall bladder.

Gallstones invariably are the cause septic Inflammation in gall bladder called Acute and Chronic Cholecystitis.

If stone passes into common bile duct, known as CBD stone, it may cause Obstructive jaundice.

Long standing stones in gallbladder, by continuous irritation of its mucous membrane can be the precursor of carcinoma of gall bladder.

Jaundice

Jaundice is due to the presence increased Bilirubin in circulation.

Bilirubin, a yellow pigment, is a natural breakdown product of red blood cells. It is conjugated and secreted by liver in bile, and is stored in Gallbladder. In response to fatty meal, through mediation by cholecystokinin, it is released with bile, into the duodenum.

In intestines it is digested and broken down to Urobilinogen, a colorless product which is absorbed and excreted in urine; and Stercobilinogen, which passes in faeces giving them the natural color.

‘Pre-Hepatic Jaundice’ or ‘Haemolytic jaundice’ is due to excessive

breakdown of red blood cells, as in Haemolytic disorders. Unconjugated Bilirubin, [Also called indirect bilirubin in liver function tests], increases in blood. It is not soluble in water; hence cannot pass in urine. However Urobilinogen is present in urine which remains of normal pale color. Stools too remain of normal color.

‘Hepatic jaundice’ is term used for jaundice associated with liver diseases. Bilirubin, direct and indirect, and most of liver enzymes are elevated in blood.

When there is obstruction in intra-hepatic ducts, it is called ‘Cholestatic jaundice’. It is invariably associated with liver damage and disorders.

‘Post-hepatic jaundice’, also called ‘Obstructive or Surgical Jaundice’ is caused by obstruction of extra-hepatic bile ducts.

Small stones can slip from gallbladder and reach common bile duct, obstructing it and causing Obstructive jaundice.

Gallstones are the commonest cause of obstructive jaundice. Tumors of Head of Pancreas and of Ampulla of Vater come next.

In obstructive or surgical jaundice, total bilirubin as well as conjugated bilirubin, [also called Direct bilirubin] are increased in blood. Alkaline phosphatase is also markedly increased. Back pressure on liver may cause liver derangements increasing other liver enzymes in blood. Coagulation function of liver may also be disturbed elevating PT and PTT. Patients of obstructive jaundice have increased tendency to bleed.

Conjugated bilirubin is water soluble; hence it appears in large amount in urine giving it dark tea color. Since no bile reaches the intestines, there is no urobilinogen in urine, and the stool is pale or colorless. Increase bile pigments in blood give yellow color to sclera, mucous membranes and skin.

Bile salts deposited under the skin cause excessive itching or pruritis.

Stones in the CBD, lead to Painful Obstructive Jaundice, which may fluctuate with movement of the stone.

Painless, Persistent and Progressive jaundice has a sinister significance, suggesting neoplasm of head of pancreas or Ampulla of Vater obstructing lower end of CBD. In such cases, gallbladder gets distended and becomes palpable, since it is not primarily diseased and is thin walled, unlike diseased thick walled gallbladder in cholelithiasis.

This phenomenon is called Courvoiser's law, which states that: 'In obstructive jaundice, if gall bladder is palpable, jaundice is not due to gallstone'.

Imaging of by Ultrasound and Magnetic Resonance Cholangio-Pancreatography [MRCP] is very helpful in diagnosis. They can show increased size of CBD, and the position of stone, if present.

However if initial ultrasound shows presence of stone in CBD; Endoscopic Retrograde Cholecysto-Pancreatography [ERCP], is preferred to MRCP, since stone can be extracted at the same time.

Ascending Cholangitis, Infection of common bile and hepatic ducts, is another serious complication of gall stones in bile ducts. E-coli from bowel are the commonest organism. Clinical presentation is by classical Charcot's triad which is 'Intermittent pain, intermittent fever and intermittent jaundice'.

Sphincterotomy [division of sphincter of Oddi], extraction of stone from CBD by ERCP is urgently required, and broad spectrum antibiotics are give. In serious cases, especially when ERCP fails, demonstration and decompression of biliary tree by Percutaneous Trans-hepatic Cholangiography [PTC] may be

required. In such cases, Vitamin K should be given before procedure to minimize bleeding from liver.

Liver Abscess

Pyogenic liver abscesses can be complications of ascending cholangitis. These are usually multiple, and are diagnosed by US or CT scan. Infected liver cysts like Hydatid cysts and portal pyemia are other causes for pyogenic liver abscesses.

They should be distinguished from Amoebic liver abscesses which usually are single and are preceded by amoebic dysentery. Small abscesses may resolve with antibiotics or anti-amoebic treatment; large ones require image guided drainage.

Acute Pancreatitis

Gallstone Pancreatitis or Biliary Pancreatitis is the commonest form of Acute Pancreatitis in Middle East and Asian countries.

Commonest cause of Acute Pancreatitis in western countries is alcohol. Other causes include trauma, hyperlipidemia, hyperparathyroidism and viral infections like mumps. When cause is unknown, it is called 'Idiopathic pancreatitis', and is presumed to be of Auto-Immune origin.

In gallstone pancreatitis, obstruction by gallstone in CBD is below its junction with pancreatic duct. Bile, under pressure, enters pancreatic duct, activates pancreatic enzymes and precipitates chemical pancreatitis. Increased pressure in pancreatic ducts causes activated enzymes to diffuse into the tissues which start the process of auto-digestion and aseptic inflammation. Invasion by bacteria converts it into full-fledged bacterial pancreatitis. Initially it may take milder form, but severity may increase depending on body resistance and

virulence of bacteria. Accordingly Acute Pancreatitis is classified as Mild, Moderate or Severe.

Severity of Acute Pancreatitis can be assessed using 'Ranson's criteria' and 'ASA scoring systems'.

In its most severe form, necrosis of pancreatic tissue ensues, causing Abscesses and Phlegmons.

Destruction of endocrine cells leads to Transient Diabetes.

Fluid, oozing from oedematous pancreas, collects in lesser sac and leads to formation of Pseudo-Pancreatic Cyst. [Cyst with no cyst wall].

If this fluid, rich in activated lipase, trickles down and comes in contact with greater omentum, it lyses the omental fat releasing fatty acids. These fatty acids saponify by trapping calcium from blood leading to Hypocalcemia. Spread of inflammation upwards may irritate stomach causing vomiting. Irritation of left dome of diaphragm may cause hiccoughs, and pain which is referred to left shoulder [Kher's sign].

In severe cases left side pleural effusion and basal pneumonia may compromise respiration and reduce oxygen saturation in blood.

Blood vessels around pancreas may be destroyed by activated enzymes, causing Haemorrhagic pancreatitis. Released blood spreads in retroperitoneal space towards loin [Grey Turner sign] and around umbilicus [Cullen's sign].

Classical clinical picture of Acute Pancreatitis is that of stabbing pain in epigastrium, radiating to the back and making patient to sit up and double up in bed pressing the upper abdomen. Nausea, vomiting and fever are associated symptoms.

Physical examination reveals tachycardia, fever, severe epigastric tenderness and guarding. Swelling in epigastrium can be felt if cyst has formed.

Other clinical features depend on severity of pancreatitis.

Elevated pancreatic enzymes, amylase and lipase, more than twice the normal, suggest diagnosis of acute pancreatitis. Since amylase may be increased in other conditions also such as acute cholecystitis and intestinal obstructions, elevated lipase is diagnostic.

Ultrasound and CT scan will show enlarged oedematous pancreas with surrounding fluid or tissue necrosis. Leucocytosis, elevated blood sugar levels, low serum calcium levels support the diagnosis. Chest x-ray and PO₂ are required in severe cases.

Treatment is conservative. NPO, IV fluids and analgesics are required. Antacids help reduce associated gastric irritation. Antibiotics are added to prevent or to treat infective stage.

Early Enteral Feeding in mild and moderate cases can reduce the harmful effects of bacterial translocation in the gut. In severe cases, calcium, oxygen and even insulin may be required. Anti-secretory agent like somatostatin helps. Role of steroids to control inflammation is debatable.

If impacted gall stone is the cause, it should be removed by endoscopic retrograde cholangio-pancreatography [ERCP].

Mild and moderate cases usually resolve with conservative treatment. Surgical management is required in severe cases and for complications.

In severe cases with generalized peritonitis, laparoscopic or open exploration of abdomen is required to washout the enzyme rich fluid, and to remove the

necrotic pancreatic tissue.

Pancreatic abscesses can be drained under imaging guidance. Mortality in severe cases is very high.

Small pseudo-cysts may resolve. Larger ones need drainage, usually internal in the stomach, by Cysto-gastostomy, performed through a gastroscope or by open method.

A period of 6-8 weeks is allowed to elapse before surgery so that the cyst forms a thick fibrotic wall around it, thus preventing leakage of enzyme rich fluid.

Chronic Pancreatitis, on the other hand has a very different aetio-pathology and management approach.

Chronic alcoholism and malnutrition are important aetiological factors. Pathological changes are those of progressive necrosis and fibrosis leading to ductal stenosis, stasis and stone formation. Symptoms are due to decreased pancreatic secretions causing dyspepsia, indigestion and steatorrhoea. Patients may suffer from recurrent attacks of severe cramping upper abdominal pain.

Diagnosis is difficult, imaging may help and pancreatic biopsy may be required to differentiate from pancreatic cancer.

Surgery in the form of removal of stones and horizontal drainage of the duct in jejunum may be required for cases where conservative treatment fails to control the symptoms.

Acute Diverticulitis

Sigmoid diverticula are multiple and are found on mesenteric border where small vessels perforate the wall, or between the taenia coli where colon wall is

vulnerable to pressure.

Sigmoid diverticulosis is a disease of middle age, and may remain asymptomatic. Symptoms occur when complications set in. These complications are Acute Diverticulitis, Severe haemorrhage, Perforation and Paracolic abscesses, and rarely Obstructions.

Acute Diverticulitis presents with acute pain in the left iliac fossa [LIF], and bowel disturbances. Tachycardia and fever accompany the condition. Leucocytosis is present. Stools may contain blood.

Local examination reveals tenderness and guarding in LIF.

Differential diagnosis includes various forms of colitis, bacterial, amoebic or ulcerative colitis.

Treatment is conservative with antibiotics.

Colonoscopy and Barium Enema are mandatory to confirm presence of diverticula, and to rule out other pathologies in colon such as cancer in elderly age group. However, these are avoided in acute stage for fear of bowel perforation.

Perforation of inflamed diverticulum leads to Paracolic abscesses which require drainage by either imaging guided catheter or by open extra-peritoneal approach.

In cases of sigmoid perforations causing general faecal peritonitis, temporary diverting tranverse colostomy is indicated.

General Peritonitis

Primary peritonitis is extremely rare. It usually occurs in females and in

children, and is caused by pneumococci.

General peritonitis almost always is secondary. It is caused by penetrating trauma and perforations of hollow viscous. Common causes are perforation of peptic ulcer, severely inflamed appendix, Meckel's diverticulum or sigmoid diverticulum. Severe form of pancreatitis can be associated with general peritonitis. It can be also be a postoperative complication.

General clinical picture is that of sepsis; with high fever, tachycardia, and leucocytosis. Abdominal signs are generalized tenderness with Board like Rigidity of abdomen. In perforations, liver dullness may be obliterated on percussion, and shifting dullness may be elicited, indicating presence of fluid in peritoneal cavity. Bowel sounds are absent, [silent abdomen]. Digital rectal examination should always be performed in all cases of general peritonitis. It helps to ascertain if there is associated pelvic collection.

Plain x-ray, upright if possible, otherwise supine or lateral decubitus, will show presence of free air in the abdomen in cases of perforations. Presence of free air in absence of perforations, suggests infection by gas forming organisms. Free air/gas can be seen in plain x-rays in post operative or post laparoscopic period. Ultrasound and CT scan are useful if clinical picture is not clear, and causes other than perforation are suspected. Diagnostic laparoscopy can be therapeutic also, in cleaning the peritoneum, closing the peptic perforation or removing the perforated appendix. Open exploration can deal with the cause, and allow a copious peritoneal lavage. In cases of perforated sigmoid diverticulum with faecal peritonitis, diversion colostomy, with or without resection, is indicated. Supportive treatment with IV fluids, NG tube and IV antibiotics is necessary.

In severe cases, patients may be in septic shock and critically ill. Critical care

monitoring in the surgical ICU is essential. This includes continuous recording of vital signs, and strict monitoring of fluid balance by intake output chart. Urinary catheter is invariably necessary since urine output is the best objective way of monitoring fluid balance. CVP line to record central venous pressure also helps in calculating the fluid requirements. Oxygen saturation by digital oxymetry helps in determining the cardio-respiratory status of these severely ill patients.

Outcome may be a complete recovery, or residual abscesses may remain. Pelvis abscesses are the commonest where pus collects due to gravity. Diarrhoea, associated with abdominal pain and fever are the usual symptoms. Rectal examination is necessary. A boggy swelling anteriorly in recto-vesical pouch may be felt. It can be satisfactorily drained through rectal wall.

Sub-phrenic abscesses result when pus collects in sub diaphragmatic spaces. They are very difficult to diagnose. US and CT scan are very useful in localizing the pus; and can be used for guided catheter drainage.

Laparoscopic or open exploratory laparotomy may be required to localize and drain residual intra-peritoneal abscesses. IV antibiotics are continued till complete resolution.

In tropical countries, Perforation of Typhoid Ulcers in terminal ileum in late stages of salmonella infection, and Ruptured Amoebic Liver Abscess may lead to general peritonitis. Exploration is necessary to deal with the situation, in addition to specific medical treatment.

Miliary form of tuberculous peritonitis can present as Acute Abdomen. It must always be considered in all cases of Unclear Acute Abdomen. Diagnostic laparoscopy and biopsy can confirm the diagnosis. Treatment is with anti-tubercular drugs.

Perforations

Perforation of hollow viscous can lead to peritonitis. Its severity will depend on the type of leaking contents from the perforated organ.

Commonest perforations are those of Peptic Ulcers which are situated on the anterior surface of first part of duodenum and along the lesser curvature of stomach. Gastric contents, usually sterile due to strong acid, leak in sub-hepatic area and flow down along right para-colic gutter. Chemical peritonitis sets in, which, as time passes, may become septic peritonitis.

Patient may be either suffering from peptic ulcer disease, or perforation may be the first event in asymptomatic silent ulcer cases.

Sudden, severe, acute epigastric pain is the presenting symptom with some nausea, retching and even vomiting. Initial severe pain in the epigastrium due to chemical irritation of peritoneum, may become less severe or even disappear after some time, a phenomenon which is known as 'Silent Interval'. This may deceive the patients who delay seeking medical advice. Pain returns after 4-6 hours and spreads all over abdomen as generalized peritonitis sets in. Pain may be referred to right shoulder if leaking air from stomach rises under the diaphragm and irritates it.

On examination, abdomen is typically distended, tender, rigid, and silent and does not move with respiration. Tachycardia, fever and leucocytosis are present.

In some cases pain and tenderness may be present in RIF, confusing the condition with acute appendicitis. Demonstration of air under right dome of diaphragm on erect x-ray of abdomen is diagnostic. In doubtful cases, imaging by US or CT scan is useful; and diagnostic laparoscopy may be required in unclear acute abdomen.

Perforation is closed with patch of omentum, [Graham's patch], through laparoscope or by open exploration. General management is the same as for peritonitis described earlier.

Perforations may also occur in acute gastritis and acute peptic ulcers caused by NSAID, steroids, and caustic ingestions. In immuno-compromised patients, symptoms may not indicate the severity of condition till septic shock sets in.

Penetrating injuries can perforate any hollow viscous leading to peritonitis.

Untreated or improperly treated cases of perforations and peritonitis may end in residual intra-peritoneal abscesses; common being Pelvic, Sub-diaphragmatic or Paracolic, requiring some form of drainage.

Abdominal Haemorrhage

Trauma is the most important cause of intra-peritoneal and retroperitoneal haemorrhage. Other causes include ruptured ectopic gestation in females, ruptured aortic aneurysm in elderly and acute haemorrhagic pancreatitis.

Trauma may be penetrating or blunt in nature.

Penetrating trauma may injure mesenteric or other major vessels leading to bleeding in the peritoneal cavity.

Blunt trauma causes rupture or laceration of solid organs, liver on right and spleen on left side. Injuries are graded on 1-6 scale. They lead to haemo-peritoneum and peritoneal irritation called 'Peritonism'. Symptoms and signs of are just like peritonitis except for septic fever. Haemorrhagic shock may be associated depending on severity of bleeding. In addition to history of trauma, there may be telltale signs such as surface lacerations, skin discoloration, haematoma of parietal wall and fracture of lower ribs. Triple contrast imaging

with CT scan is part of ATLS protocol, and a great help in diagnosis of injury and its severity. In injuries of less severity, patient may remain haemodynamically stable and bleeding stops by body's own coagulation mechanism. Treatment is supportive by IV fluids and blood transfusion when necessary.

If haemorrhage is severe, or fails to stop leading to haemodynamic instability, surgical exploration becomes necessary. Bleeding can be controlled by packing, ligation and suturing and by the topical use of glue. Liver lacerations can be repaired with deep sutures. If it fails to control the haemorrhage, tamponade by packing the liver can be effective. Packs are removed after 24-36 hours when patient becomes stable.

Splenectomy or partial liver resection becomes necessary in severe grades of lacerations. However, spleen should be preserved as far as possible.

Patient on conservative management should stay under observation for at least a week; since subcapsular haematoma may suddenly rupture, starting fresh bleeding; called 'Secondary Apoplexy'.

Retroperitoneal haemorrhage has two distinct entities.

When bleeding starts from above and tracks downwards, it usually is due to leaking large vessels; and must be explored.

When it starts from below and spreads upwards, it is due to oozing venous plexuses as in major pelvic trauma or after major pelvic operations. Tense pelvic fascia has tamponade effect. Exploration is contraindicated since it can result in uncontrollable bleeding.

In haemorrhagic type of acute pancreatitis too, blood may collect in retro-peritoneal space and spread laterally and anteriorly. This results in Grey

Turner sign [dark discoloration in loin] and Cullen's sign [dark discoloration around umbilicus]. Dullness on left side only which shifts to right when patient is turned suggests blood or blood clot in left flank [Balance's sign].

Upper GIT Haemorrhage

This presents as haematemesis and/or malaena.

Vomited blood is dark in color [like coffee ground] due to conversion of haem pigment of blood into acid haematin in stomach. Further breakdown of blood in intestines causes dark and smelly stools, called malaena.

Common causes of upper GI bleeding are oesophageal varices in portal hypertension, chronic peptic ulcers and acute erosive gastritis. Rare causes are Mallory Weiss syndrome, vascular lesions of stomach and gastric tumors; polyps and cancers.

Bleeding can be massive leading to haemorrhagic shock. Gastro-duodenoscopy is diagnostic for the source of bleeding. Upper GI contrast studies are useful during interval between bleeding episodes.

Bleeding from oesophageal varices can be controlled by injecting vasoconstrictors or sclerosing agents, or by banding of oesophageal varices.

In bleeding peptic ulcers, electro or laser coagulation, injecting vasoconstrictors or sclerosing agents around the bleeding point can stop the haemorrhage. Success rate of endoscopic treatment is very high.

Other methods include use of very cold saline in gastric erosions; and tamponade of oesophageal and gastric fundal varices by the use of Sangstaken Blakemore tube. Nowadays open surgery is rarely required to deal with bleeding lesions.

Elective or emergency surgical management of portal hypertension by shunt procedures may be required. Transjuglar Intrahepatic Porto-systemic Shunt [TIPS] is the popular choice.

Supportive measures to maintain haemodynamic equilibrium are necessary and include IV infusions and blood transfusions, and use of tranquilizers and sedative drugs. Infusion of octreotides and vasopressin can be useful.

In all cases of GI haemorrhages, bleeding disorders must be considered and should be excluded.

Lower GIT Haemorrhage

Severe bleeding, fresh and red in color, occurs from colonic lesions. In cases of massive upper GI bleed with quick intestinal transit time, fresh red blood, rather than malaena stool, may pass per rectum.

Common causes are colonic polyps, ulcerated or fungating cancers, ulcerative colitis and sigmoid diverticulosis. Rarely internal haemorrhoids may be the source of severe bleeding.

Colonoscopy can locate the bleeding lesion and a biopsy, can confirm its nature. Barium enema is useful in diagnosing the cause after bleeding has stopped. Management is by resuscitation, IV infusions and blood transfusion. Pedunculated polyps can be removed endoscopically by snare. Bleeding can also be controlled by injecting sclerosing agents around the bleeding point as described for upper GIT bleed. Surgical resections as emergency or as elective procedure may be required when conservative methods fail.

Angiodysplasias must be considered in elderly, when no obvious lesion is revealed by colonoscopy. Selective colonic angiography and radioactive scinti-scans can help locate the lesion. Radiology guided embolization of

bleeding vessel can stop the haemorrhage.

Only other abdominal haemorrhages of significance are of gynaecological origin such as ruptured ectopic pregnancy causing haemoperitoneum.

Haematuria from urinary tract results from urinary stones, enlarged prostate and tumors of kidneys and urinary bladder. Renal, urinary bladder or urethral injuries also result in haematuria.

Haematochaezia is fresh bleeding per rectum. Commonest cause in infants is acute anal fissure, in children they are juvenile polyps; in adults, internal haemorrhoids; and in elderly, rectal cancer must be considered.

Obstructions

Acute Intestinal obstruction closely follows inflammations in frequency as the cause of acute abdomen.

There are many ways to look at and classify intestinal obstructions.

- By function: it may be dynamic [mechanical], or a-dynamic [paralytic].
- By onset: it may be acute, sub-acute, chronic and acute-on-chronic.
- By position: it may be high [proximal], and low [distal] to ileocaecal valve.
- By grade: it may be partial or complete.
- By aetiology: it may be intraluminal, intramural, extramural.
- By pathology: it may be congenital, mechanical, inflammatory, or neoplastic.
- By severity, it may be simple, close loop, and strangulating in nature.

- By frequency: obstructed hernias, postoperative adhesions, strictures in inflammatory bowel diseases like tuberculosis and Crohn's disease, and neoplasm are the common causes.
- By age: In infants and children, ano-rectal malformations intestinal malrotations, congenital bands, Hirschsprung's disease, and intussusceptions are likely causes. In young and middle aged adults, post-operative adhesions, obstructed hernias, and inflammatory strictures are the usual causes. In old and elderly faecal impaction, volvulus and tumors must be considered.

Pathophysiology of the process explains most of the symptoms and signs in mechanical obstructions.

Typical symptoms are Colicky abdominal pain, Vomiting, Distension of abdomen and absolute Constipation.

Initial response of the body is to propel and expel the obstructive agent, by increasing the force and frequency of peristaltic contractions. This results in colicky pain. In an attempt to give rest to the blocked bowel, anorexia and nausea sets in. Vomiting evacuates the bowel above the obstruction. After evacuating the residual contents from below, there is absolute constipation; nothing passes, no faeces, not even flatus. Eventually, proximal bowel starts filling up causing abdominal distention, central if only small bowel is distended, and of flanks, if colon is distended. Increased peristalsis may be visible in thin patients; but on auscultation, bowel sounds are always increased. Digital rectal examination reveals empty ballooned rectum.

In high obstructions, vomiting is early, absolute constipation is late. Just the opposite happens in low obstructions; constipation is early but vomiting is late.

Plain x-ray film of abdomen and pelvis showing multiple air fluid levels clinches the diagnosis. A 'Sentinal loop' of bowel suggests internal strangulation by band or internal herniation. Estimation of serum electrolytes guides their replacement by IV infusion.

In simple obstructions, mortality is not due to obstruction per se, but because of ensuing fluid and electrolyte imbalance. Average adult human body loses eight liters of fluid daily in GIT; four liters above the ligament of Treitz, as saliva, bile, gastric and pancreatic juices; and four liters below as small bowel juices [Succus Entericus]. Fortunately most of the water is reabsorbed in colon, thus restricting the daily fluid loss from GIT to less than half liter. Imagine that because of obstruction, all the fluid in intestine does not reach the colon for re-absorption, and is lost to circulation in dilated bowel; how much dehydration and electrolytes loss will result!

Resulting dehydration, metabolic alkalosis, hyponatraemia and hypokalaemia have disastrous effect on vital organs like brain, heart, and kidneys.

Principals of management, therefore includes The Four 'R'. Remove, Replace, Restore, and Release.

Remove collection above the obstruction by nasogastric tube aspiration or suction; this stops vomiting, prevents aspiration in airways, reduces distension and gives rest to overworking intestines. Obstructing faecal matter in rectum and colon can be removed by enemas. Urine is removed by a catheter to record hourly output. This is the most objective way to measure dehydration and the amount of fluid replacement.

Replace intravenously what is lost as measured by 24 hrs urine output and NG tube aspirate, and add daily requirement of 2 liters.

Restore normal fluid, electrolyte and acid base balance. Check serum electrolytes daily and adjust the IV fluid composition accordingly. All this is important before attention is paid to obstructing agent, its pathological nature and surgical management.

Release the obstruction surgically, where necessary, by dividing the adhesions, resecting the lesion and restoring the continuity by anastomosis; or if obstruction cannot be removed, by bypassing it.

Closed loop obstructions, are dangerous as they lead to early strangulation, ischaemia, and gangrene of the bowel. Severity of pain, fever, tenderness, leucocytosis and haemodynamic disturbance such as tachycardia and hypotension suggest strangulation. Early action by surgical exploration is mandatory to prevent disaster.

Examples of closed loop obstructions are Strangulated External and Internal Abdominal Hernias, Intussuception, and Volvulus. Even distal colonic obstructions becomes close loop, if ileocaecal valve is patent.

Intussuception is common in children, and usually of ileo-colic variety. Swollen lymphatic patches called Peyer's patches lead the way, advancing with peristalsis, taking the terminal ileum forwards, first in caecum and then in ascending colon. Eventually whole caecum may disappear in colon leaving empty RIF and forming a sausage shaped mass in upper abdomen.

Child cries intermittently with colicky pain, and may pass stools mixed with mucous and oozing blood from ischaemic head of advancing intestinal tube [Red Currant Jelly Stool]. A thin barium enema in saline helps in diagnosis and can reduce early intussusceptions by hydrostatic pressure. If it fails, operative reduction is required.

Volvulus is twisting of a loop of intestine around its vascular mesenteric axis. Sigmoid volvulus is the commonest site, because the sigmoid loop is mobile and usually lies redundant in pelvis. When it accommodates large amount of faeces, it swings like a pendulum around its narrow mesocolic attachment.

A 90 degree twist may be reversible, but 180 degree twist causes obstruction. Passage of contents from the loop stops, bacterial fermentation of contents releases gases which distend the loop like a huge doubled up balloon. It rises up in abdomen giving coffee bean appearance in plain x-ray films of abdomen.

Any twist more than 180 degrees, if left alone, will definitely lead to strangulation. Wall of distended fundus of the loop may undergo ischaemic necrosis, causing a leak and general faecal peritonitis.

Volvulus is common in advanced age. Symptoms are huge tender distended abdomen and absolute constipation. Vomiting is late.

Passing a rectal tube through rigid sigmoidoscope is usually successful in deflating and untwisting the loop. It must be considered as the initial step in treatment, unless there is evidence of peritonitis or if patient is haemodynamically unstable. Operative treatment includes derotation and decompression, or resection and anastomosis where necessary. In very sick patients, exteriorization of the loop or resection with temporary colostomy [Hartman's procedure] is other option. Continuity of bowel can be restored later.

Intestinal Ascariasis in tropical countries may lead to intraluminal intestinal obstruction caused by a bolus of round worms which are entangled with each other. Conservative management is usually successful. Anti-helminthic syrup through NG tube can be tried to dislodge them. In unsuccessful cases or with perforation and peritonitis, exploration becomes necessary.

Sub-Acute, Chronic and Recurrent Obstructions

These types of obstructions are due to adhesions, bands or strictures due to tuberculosis and Crohn's disease. Tumors cause progressive obstruction as they grow in size. Imaging with contrast, in the form of gastrograffin meal and follow through, small bowel enema by oral route, or colon enema from below, is necessary to diagnose. Thick barium is avoided since it can precipitate complete obstruction. There are no specific tests to diagnose these conditions. Diagnostic endoscopy and biopsy certainly helps, and histology is the final answer. Therapeutic trial of specific chemotherapy may be diagnostic if response is positive.

Adynamic Obstruction

Pathophysiology of this condition, also called 'Paralytic Ileus' is quite different from mechanical obstructions.

Intestinal movements can be paralysed due to trauma, operations, generalized inflammations, electrolyte imbalance such as hypokalaemia, and due to effects of neurotropic drugs. There is no real block of intestinal lumen; it is just that there is no active propulsion due to absence of peristalsis.

In such cases there is huge distension of abdomen, pain is dull and continuous all over the abdomen, and vomiting is like passive regurgitation. Instead of constipation, patient may continue to pass gas and fluid faeces. Bowel sounds are absent [silent abdomen]. Rectal examination shows presence of faeces.

Treatment is conservative with NG tube aspiration and IV fluid replacement, till peristalsis returns. Electrolytes are corrected and antibiotics are added if peritonitis is present.

Mesenteric Ischaemia

This presents with severe cramping pain in abdomen, which can be intermittent as in patients with sickle cell disease, or progressive as in old age due to atherosclerotic changes in mesenteric vessels. Physical signs are minimal, and are not consistent with the severity of pain. Diagnosis is suspected in Elderly, Sicklers and Diabetics. It is by the process of exclusion of other pathological conditions causing similar symptoms. Expert radiologist may find suspicious signs on CT scan. Mesenteric angiography may be required to confirm the diagnosis. Treatment is conservative. Exploration may be required if gangrene of the bowel and peritonitis sets in.

Abdominal Masses [Including Tumors]

Logical steps towards diagnosis of abdominal masses should be based on the anatomy and the probable pathology of the mass. Combination on information on these two aspects is the key to diagnosis of abdominal masses as explained below.

Anatomical Approach

Abdomen is arbitrarily divided into NINE quadrants by two vertical lines drawn from mid-clavicle point to the mid-inguinal point on both sides; and two horizontal lines; upper being midway between supra-sternal notch and pubic symphysis and the lower joining the two tubercles on iliac crest. These quadrants are right and left hypo-chondriums, [RHC, LHC,] lumbar regions and iliac fossae on left and right side [RIF, LIF]; and epigastrium, umbilical and hypogastrium from above down in the middle.

A mass in any quadrant is most likely to arise from the anatomical structures in that quadrant. For example a mass in RHC most likely mass is of liver

[Hepatomegaly] or gallbladder, in epigastrium, stomach or pancreatic mass, and in LHC the splenomegaly. Masses in lumbar regions are most likely from kidneys or colon, and in umbilical region from intestines or mesentery. Iliac fossa masses invariably are from bowel or from uro-genital organs. Commonest Hypo-gastric mass is full urinary bladder or gravid uterus. Bladder tumors come next.

Another anatomical approach is to divide masses located in three regions; Parietal, intra-abdominal and retro-peritoneal.

Simple head raising and straight leg raising tests can differentiate between parietal masses which become more prominent, and intra-abdominal masses which disappear during the tests. Retro-peritoneal masses invariably are fixed and cannot be moved.

Common parietal mass/ swelling in abdominal wall are hernias.

Common intra-abdominal masses are arising from bowel and mesentery and are either inflammations or tumors. Pelvic masses are of genitourinary origin.

Common retroperitoneal masses arise from lymph nodes or are of vascular origin. Kidneys, although retroperitoneal, usually present as intra-abdominal masses.

Pathological Approach

Abdominal masses can also be classified based on probable pathology as suggested by symptoms and signs.

Common Congenital masses are related to mal-descended testes, and are usually found in young males.

Any parietal mass following Trauma is likely to be a Haematoma.

Other than Organomegaly, abdominal masses may be of various pathological origins.

Inflammatory masses in different quadrants of abdomen are the commonest. These include; Appendicular mass, Hyperplastic Ileocaecal Tuberculosis and Regional Ileitis in RIF; Diverticular mass in LIF; Inflamed gall bladder in the right hypochondrium, and Pseudopancreatic cyst in epigastrium.

Abdominal tuberculosis usually presents in four forms; Ulcerative intestinal lesions, Hyperplastic ileocaecal tuberculosis, Tubercular mesenteric adenitis, and Tubercular peritonitis; this later is either dry adhesive or wet ascitic form.

Fulminating military tubercular peritonitis may present as acute abdomen. Laparoscopy/exploration shows small yellowish nodules all over the visceral and parietal peritoneum. Histology confirms the diagnosis.

Tuberculosis [TB], being a disease of lymphatics, causes protein rich fluid to ooze out from diseased glands. This leads to 'Adhesions', which is an important feature of tuberculosis. Intestines get matted together, and to the covering peritoneum.

Abdominal TB can produce 'vague abdominal masses which mimic any pathological lesion, especially tumors; carcinomas and lymphomas'. Symptoms of abdominal TB are usually vague. On palpation, abdomen may have a peculiar 'Doughy feel'.

Diagnosis is a dilemma. Presentation is late, usually with complication of intestinal obstruction. Being a disease of fibrotic nature, perforations and haemorrhages are rare, except in ulcerative form of small intestinal tuberculosis.

Crohn's disease also mimics tuberculosis. However ulcerations, perforations and fistulations, external and internal, are common in this disease.

In ulcerative colitis too, ulcerations, perforations and haemorrhages are common complications.

In tropical countries, where ‘Amoebiasis’ is common; amoebic colitis may mimic ulcerative colitis, and caecal amoeboma may resemble hyperplastic ileocaecal TB.

Exhaustive investigations; laboratory, imaging and endoscopic are required to arrive at a diagnosis in inflammatory masses. At times diagnosis is a postoperative histological surprise.

Treatment of all the chronic inflammatory bowel diseases is primarily medical with specific chemotherapy.

Indications for surgery are either for diagnosis or for the management of complications which include obstructions, perforations leading to abscesses and fistulations, or severe haemorrhages.

Non inflammatory non neoplastic mass in abdomen includes Mesenteric Cyst, which typically moves across the attachment of mesentery.

Tumors form the largest group of non inflammatory surgical masses in abdomen.

Diagnosis of carcinoma of stomach, pancreatic tumors and colonic cancers in epigastrium, carcinoma of gallbladder in right hypochondrium, colon cancers and renal tumors in lumbar regions must be considered.

Hypogastric masses could be full distended urinary bladder, or bladder tumor; and adenexal tumors in females.

In children, Wilm’s tumor may fill the whole abdomen. Tumors of undescended testes may present as abdominal mass.

Lymphomas should always be considered in all abdominal masses. Hepato-splenomegaly may be associated.

Metastatic tumors in abdomen may come from as remote areas as the breasts. Krukenberg tumor of ovaries is an example of metastatic tumor by trans-coelomic spread.

Term GIST is applied to gastrointestinal stromal tumors which can present as an abdominal mass.

Peutz-Jegher syndrome is intestinal hamartomatosis. Polyps of varying sizes occupy almost whole of small intestine and may cause haemorrhages and intussusception.

Carcinoid tumors arise from neuro-endocrine cells. Appendix is the common site. They are very small in size and diagnosis is a histological surprise after appendectomy. Functional tumors present as carcinoid syndrome, with flushing attacks and asthmatic attacks, borborygmy and diarrhoea. These symptoms are due to the release of vaso-active peptides, 5-hydroxytryptamine [serotonin], and appear in urine as 5-hydroxyindoleacetic acid, [5-HIAAA]. Malignant carcinoid tumors metastasize in liver.

Diagnosis of abdominal masses depends on good history, thorough physical examination including bimanual examinations, digital rectal/vaginal examinations and appropriate investigations. These include laboratory, imaging techniques and upper and lower GI endoscopies and diagnostic laparoscopy. Tumor markers like CEA may help in diagnosis and prognosis. Histology of either biopsy or resected specimen is the final arbitrator, confirming the diagnosis. Staging of tumor depends on the extent of its spread, and decides the prognosis. Duke's method of staging applies to colorectal cancers.

Treatment is usually surgical which, in principle, involves wide radical resections and reconstructions. This may be performed as single stage procedure or may require staged approach. Adjuvant and neo-adjuvant chemotherapy may help. Lymphomas may melt with chemotherapy. Most of the cancers are radio-resistant, but combination neo-adjuvant chemo-radiation may downstage the rectal tumors.

Research in genetics and molecular biology is opening newer avenues in diagnosis, prognosis and management of tumors in general and GIT tumors in particular, specially colorectal cancers.

Tumors of Colon

Colorectal cancers are increasing in frequency all over the western world, mainly due to changing diet and bowel habits. It has replaced lung cancer as the commonest fatal cancer in males. In females it comes next to breast cancer which is now the commonest fatal cancer and has replaced cervical cancer which used to be on the top of the list.

In eastern countries of the world, upper GI cancers like those of oesophagus and stomach are still the commonest cancers.

Benign tumors of colon are called polyp.

They may be single or multiple, hereditary or non hereditary, familial or non familial and pedunculated or sessile. Most of them are premalignant. Pseudo-polyps and hypertrophic polyps associated with ulcerative colitis also have malignant potential

Familial adenomatous polyposis [FAP] is defined as more than hundred colonic polypoid adenomas. 80% of them are familial, 20% arise as mutation of

adenomatous polyposis coli gene [APC]. History of colon cancer at early young age is invariably present. Condition is definitely premalignant. Screening of all the family members is mandatory.

Hereditary Non-Polyposis Colorectal Cancer [HNPCC] is also called 'Lynch syndrome'. This has 80% life time risk of developing colorectal cancer. It can be diagnosed by genetic testing or by 'Amsterdam criteria'.

Colon Cancers

Recto-sigmoid colon is the commonest site for cancers followed by caecum and ascending colon.

Stasis of solid and semisolid faecal matter in sigmoid colon provides prolonged contact and time for interaction for carcinogenic end products of metabolism with colonic epithelium leading to dysplasia and anaplasia. This may explain why recto-sigmoid is the preferred site for cancer. Low fiber diet and irregular bowel habits are definitely related to epidemiology of colon cancers.

Microscopically most of colon cancers are adenocarcinoma.

Macroscopically they may take the form of malignant ulcers, polypoidal fungating cauliflower like masses, localized malignant stricture or long tubular infiltration of colon wall.

Tumor spreads to neighboring structures by infiltration, to mesocolic nodes through lymphatics, and to liver by portal blood.

TNM Staging of Cancer is based on this spread. Histological differentiation grades the tumor as 'Well differentiated, moderately differentiated and undifferentiated or anaplastic'. Both, stage and grade, determine the treatment

and prognosis.

Right sided cancers are polypoidal and ulcerating leading to slow blood loss. They present with iron deficiency anaemia, anorexia and asthenia. A palpable mass may be the first presentation. Left sided cancers are constricting, leading to increasing constipation. Intestinal obstruction may be the first presentation.

Altered bowel habits, alternating constipation and diarrhoea, increasing constipation, recent onset of piles or rectal bleeding, especially in elderly are warning symptoms. Treatment of haemorrhoids of recent onset in people above forty must be preceded by sigmoidoscopy.

Contrast imaging studies and colonoscopy with biopsy may clinch the diagnosis. CT scan shows the extent of the disease. CEA may be raised.

Localized colon cancers are treated by radical resections; right or left hemicolectomy, transverse or sigmoid colectomy, as the case may be.

All forms of polyposis coli and cancers arising in ulcerative colitis require total procto-colectomy, ending in permanent terminal ileostomy. Sphincter preserving resections with construction of ileal pouch and ileo-anal anastomosis are preferred. Procedures can be performed by open or laparoscopic technique.

Screening for colorectal cancers is a subject of debate. Occult blood in stool in high risk population is useful when positive. Screening colonoscopy is advised for familial cancers and for those with positive family history.

Post-operative follow up must include estimation of CEA; rising levels may suggest either recurrence or metastases.