


Chapter 4



Thyroid Gland

4.1 Goiter

Swelling in the anterior triangle of neck, which moves with swallowing, is most likely thyroid swelling called '*Goiter*'.

Thyroid uniformly enlarges in response to increased metabolic demands at the time of puberty, pregnancy and lactation. This is called '*Physiological goiter*' (4.1a, 4.1b).

Genetic factors affecting the enzymes controlling the chemical reactions in the thyroid can also cause goiters. Such goiters may be familial in nature.

Many members of a family may have goiter if their common food and water is deficient in iodine. This is called '*Endemic or iodine deficiency goiter*' (4.1c).

Such goiters usually take the shape of many nodules in thyroid called '*Multinodular goiter*' (4.1d).



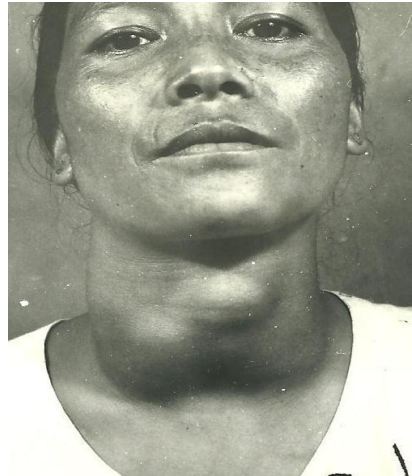
4.1a



4.1b



4.1c



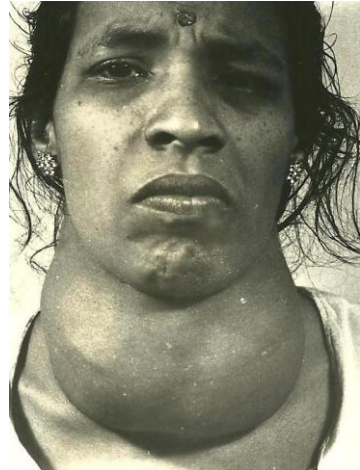4.1d

4.2 Multinodular Goiter

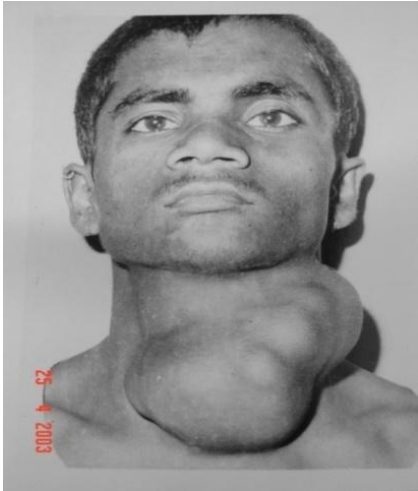
More examples of multinodular goiter are seen on the facing page (4.2a, 4.2b, 4.2c, 4.2d).



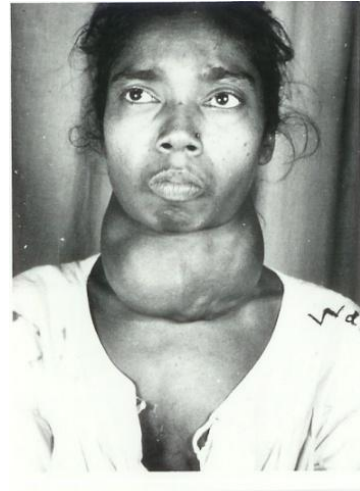4.2a



4.2b



4.2c

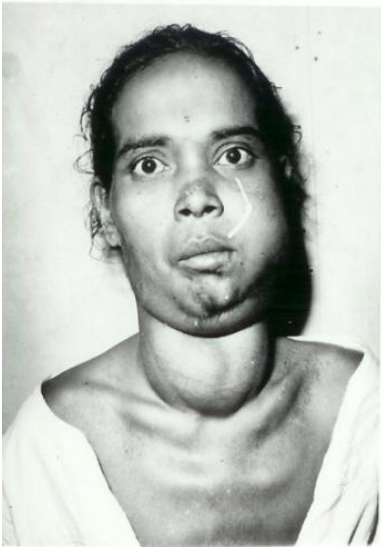

4.2d

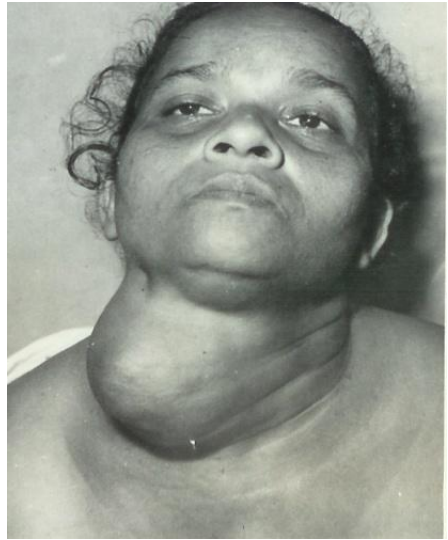4.3 Solitary Thyroid Nodule

Solitary thyroid nodules are always a diagnostic dilemma (4.3a).

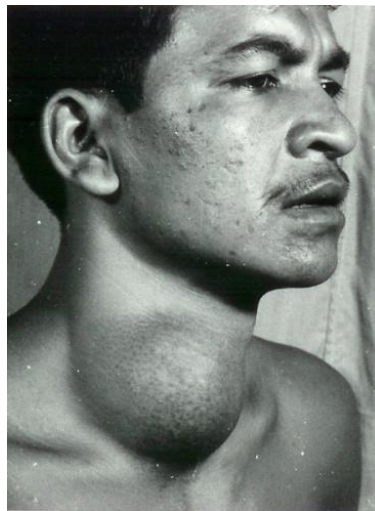
They may be solid (4.3b) or cystic (4.3c). Pathologically they may be benign or malignant. Imaging and Fine-needle aspiration biopsy (FNA) help in diagnosis.



4.3a



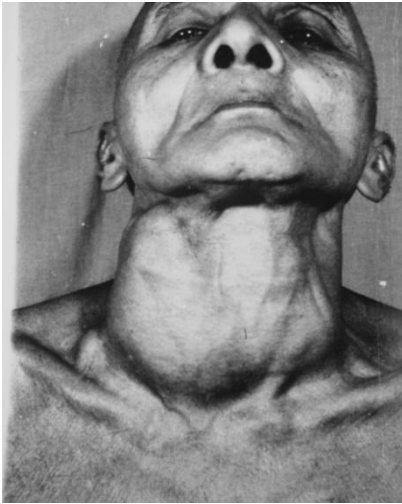
4.3b



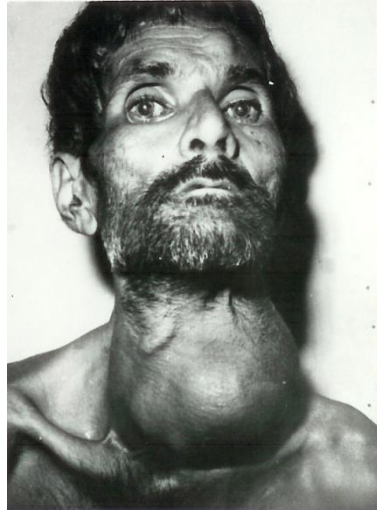4.3c

4.4 Malignant Goiter

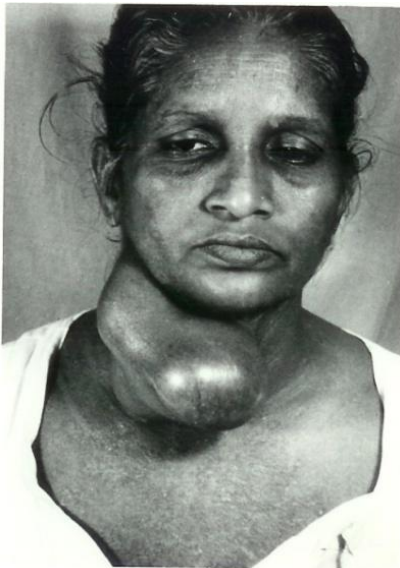In some cases the malignant nature of the tumor is obvious by evidence of venous compression (4.4a, 4.4b) or lymph node enlargement (4.4c, 4.4d).



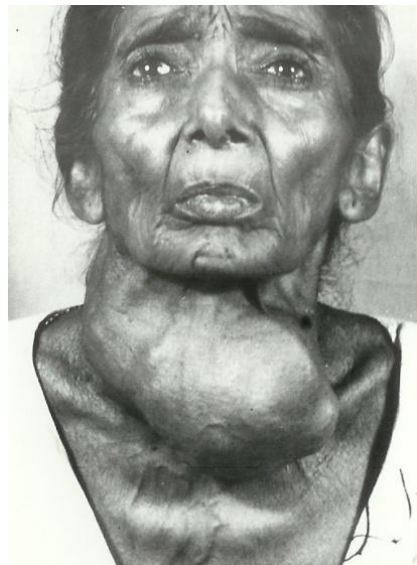4.4a



4.4b



4.4c



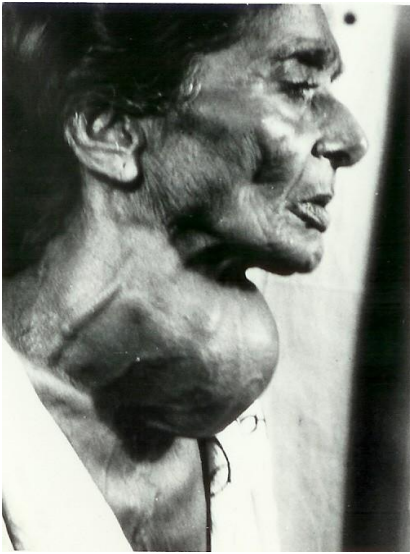
4.4d

4.5 Malignant Goiter [Contd.]

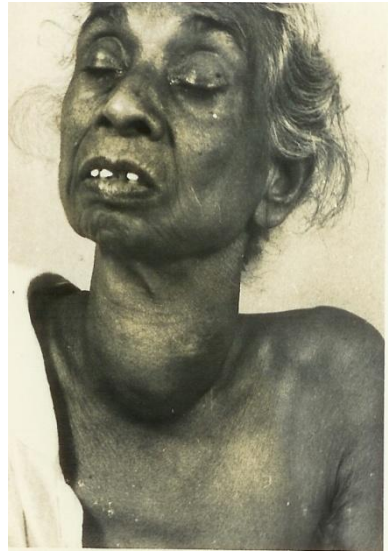Anaplastic tumors of thyroid with venous compression. (4.5a)

Small but hard enlargement of the thyroid is fibrotic “Riedel’s Struma”.
Diagnosis depends on histology (4.5b).

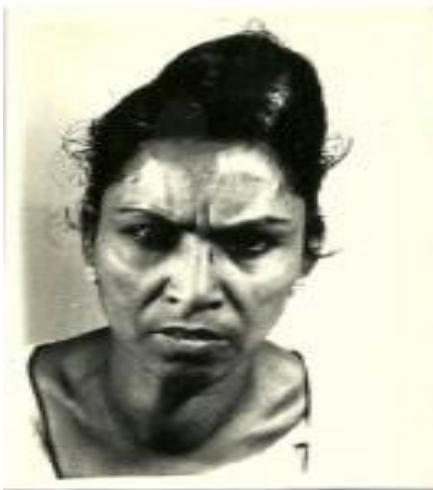Follicular or anaplastic tumors may spread by venous stream. Such blood borne metastases can be found in the lungs or bones, especially cranial bones (4.5c, 4.5d). They are usually very vascular and may be pulsatile on palpation.



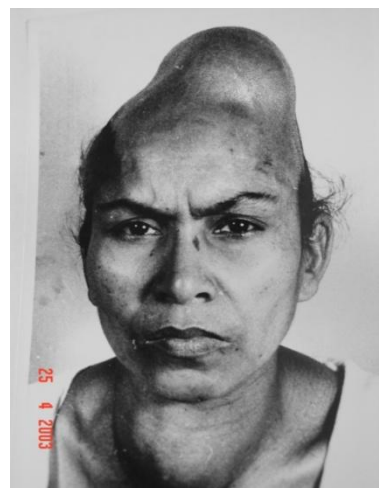
4.5a



4.5b



4.5c



4.5d

